

انتطاصي اناتومي

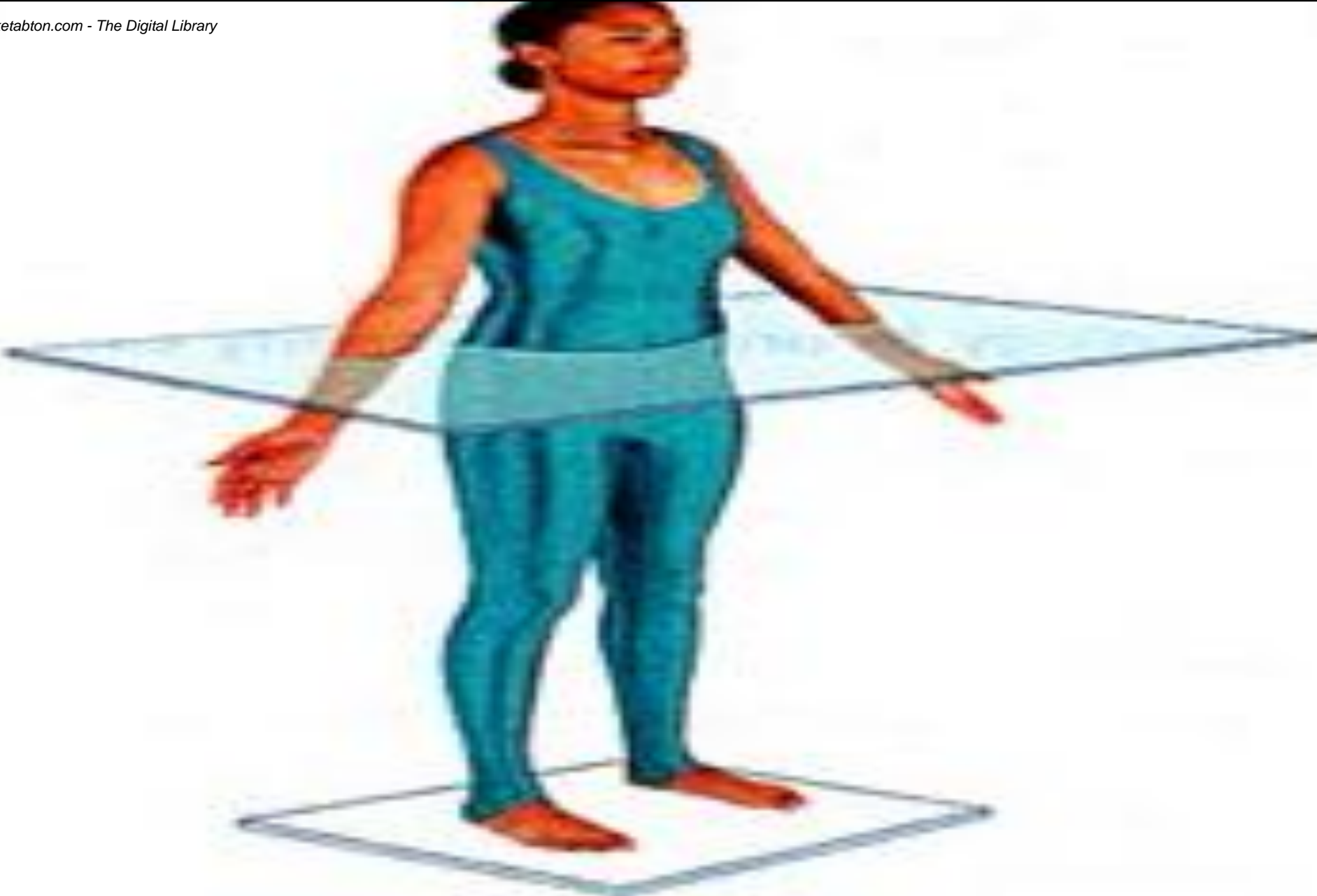REGIONAL ANATOMY OF HEAD & NECK

Dr. Asadullah Bisharat

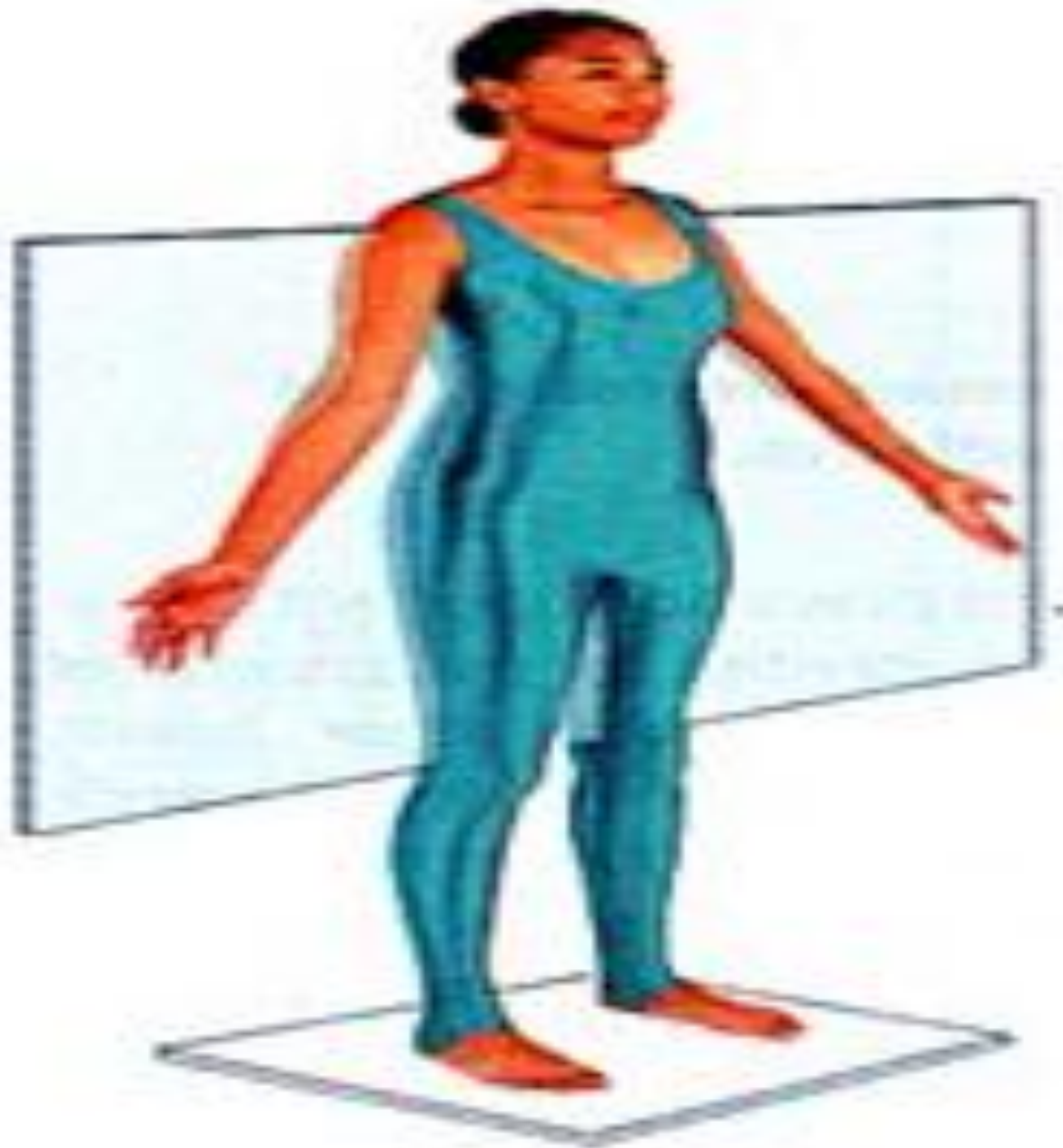BDS, BLS (The University of Lahore, Lahore) 2014

کتاب پیاوری

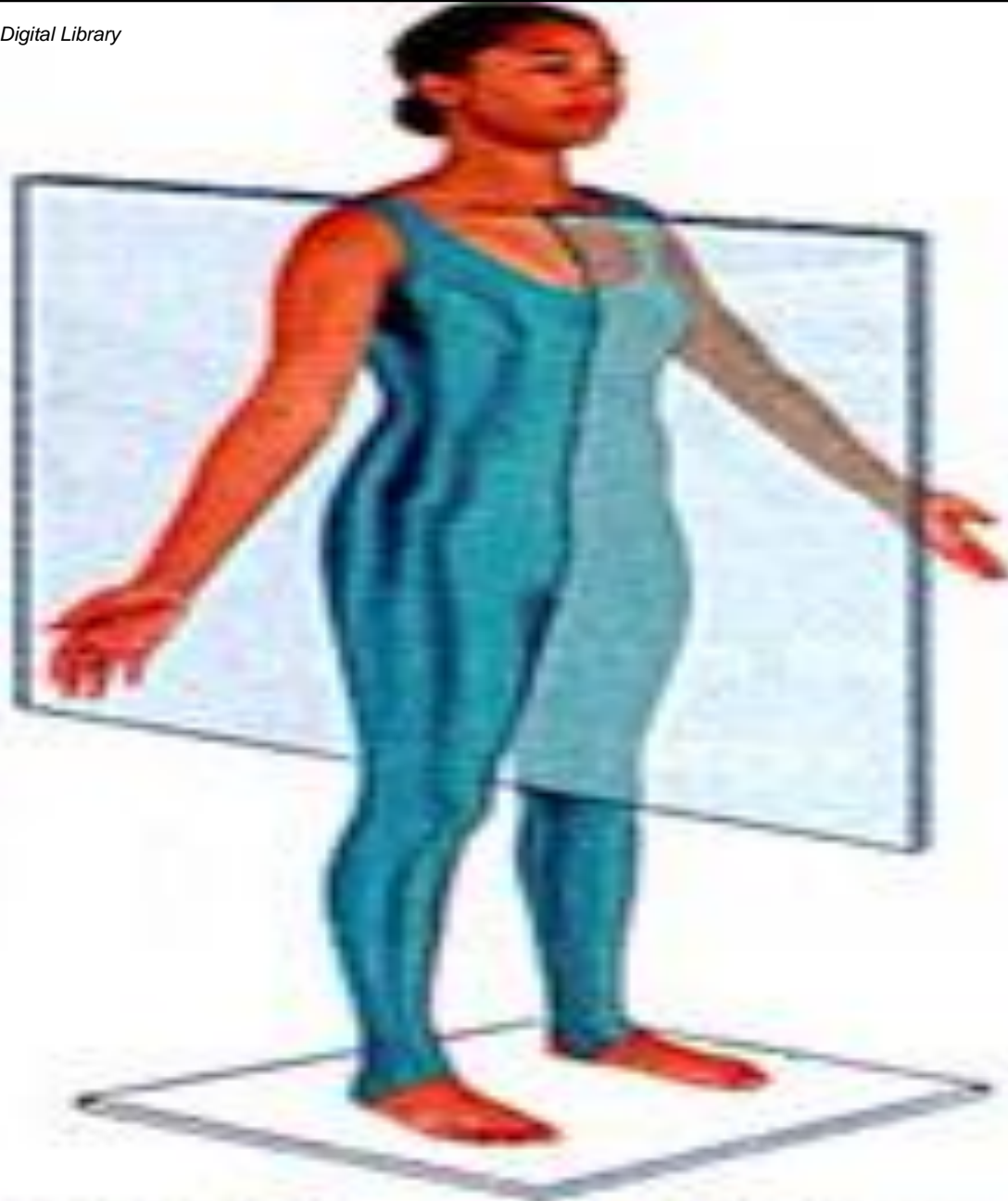Ketabton.com



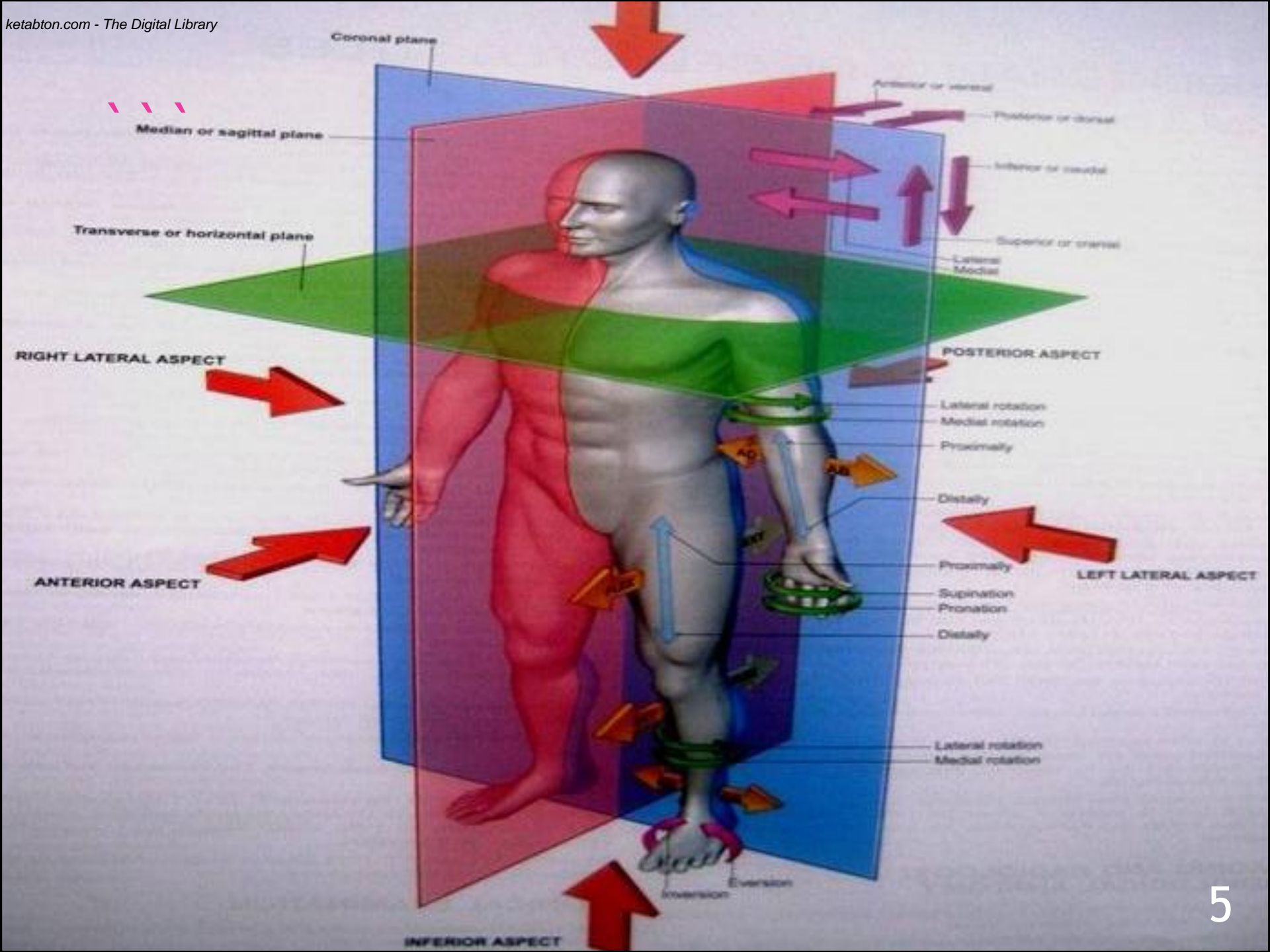
(c) Transverse Plane

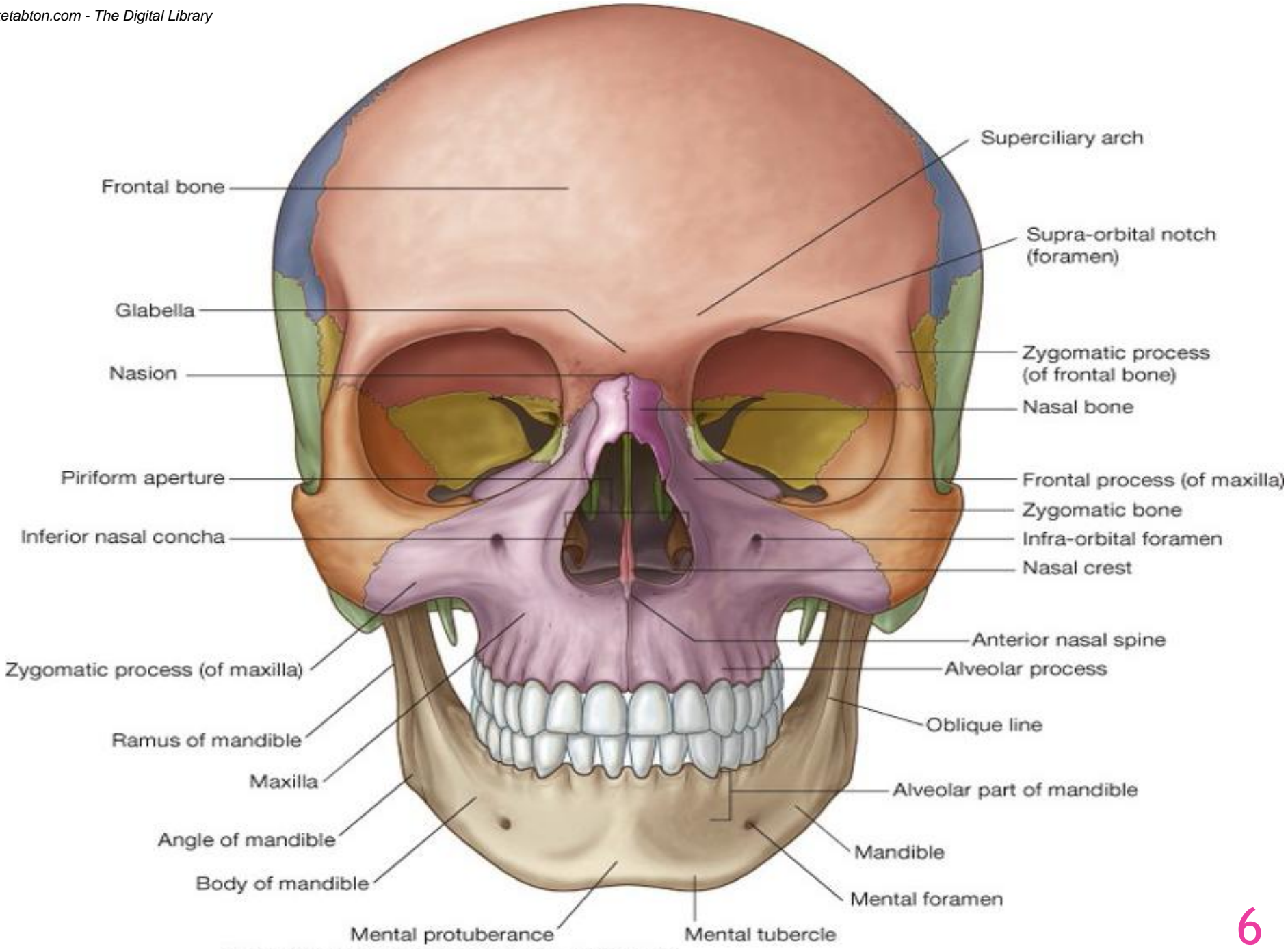


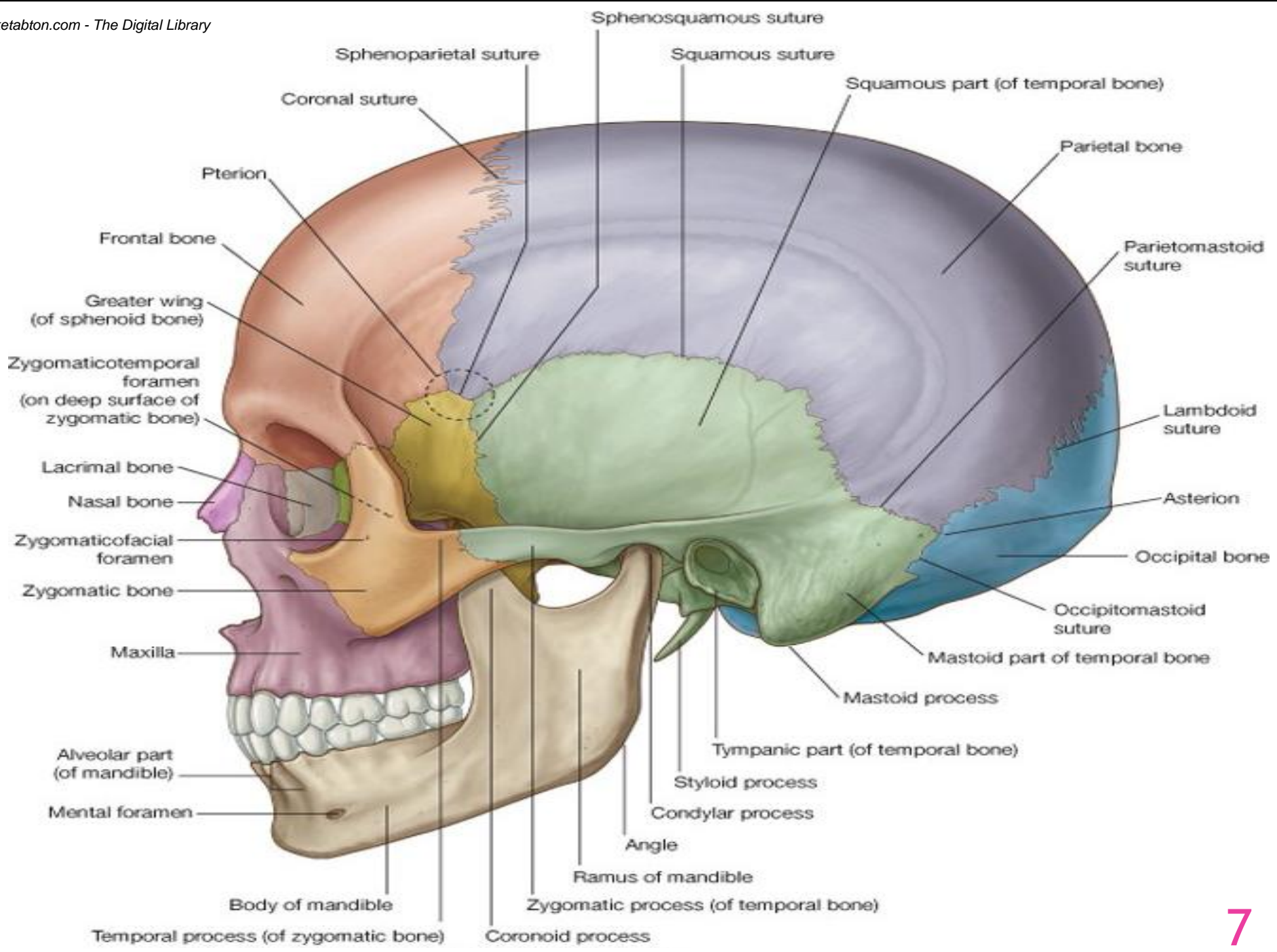
(b) Frontal(Cronal)Plane

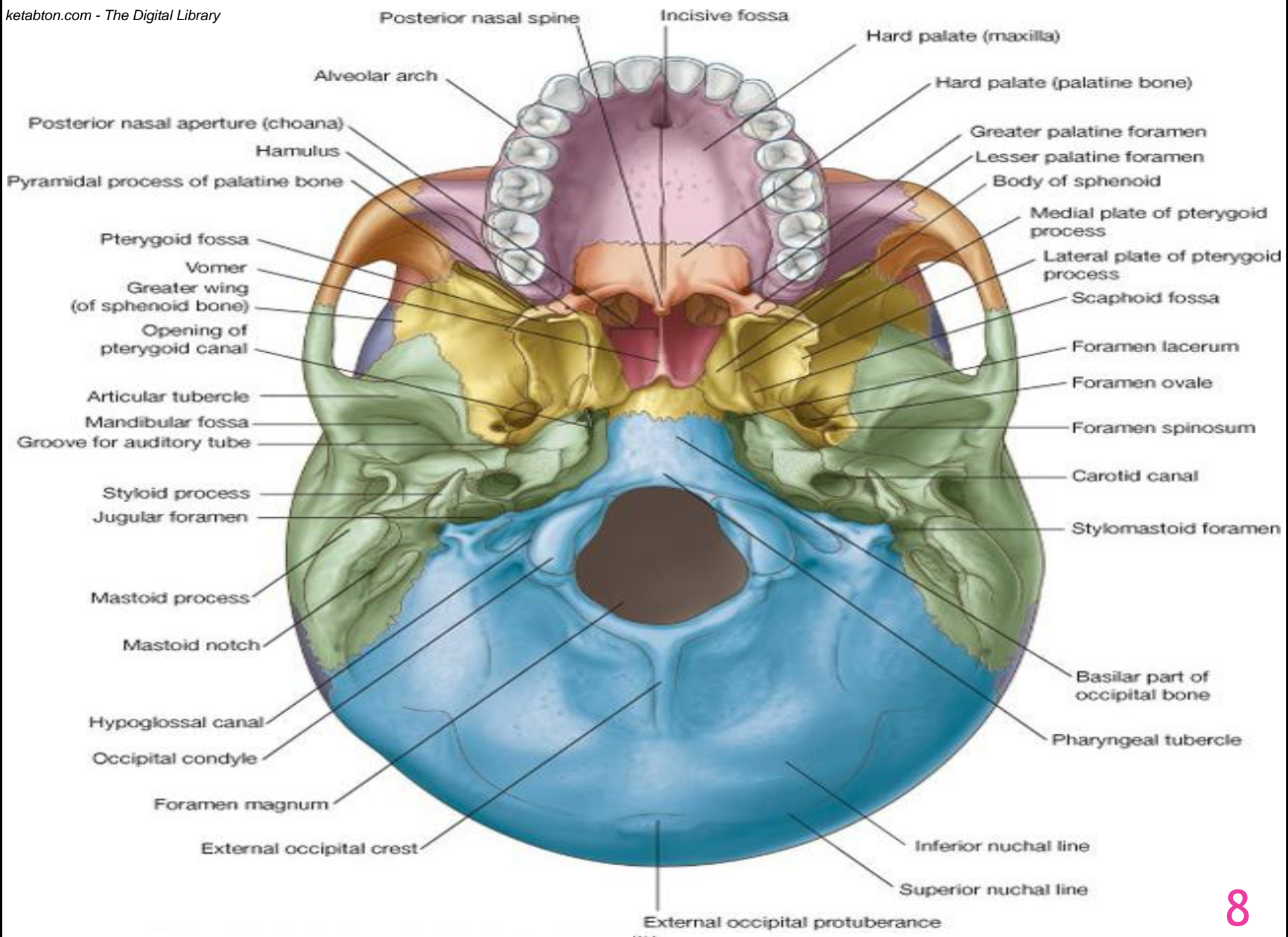


(a) Midsagittal(Midian)Plane

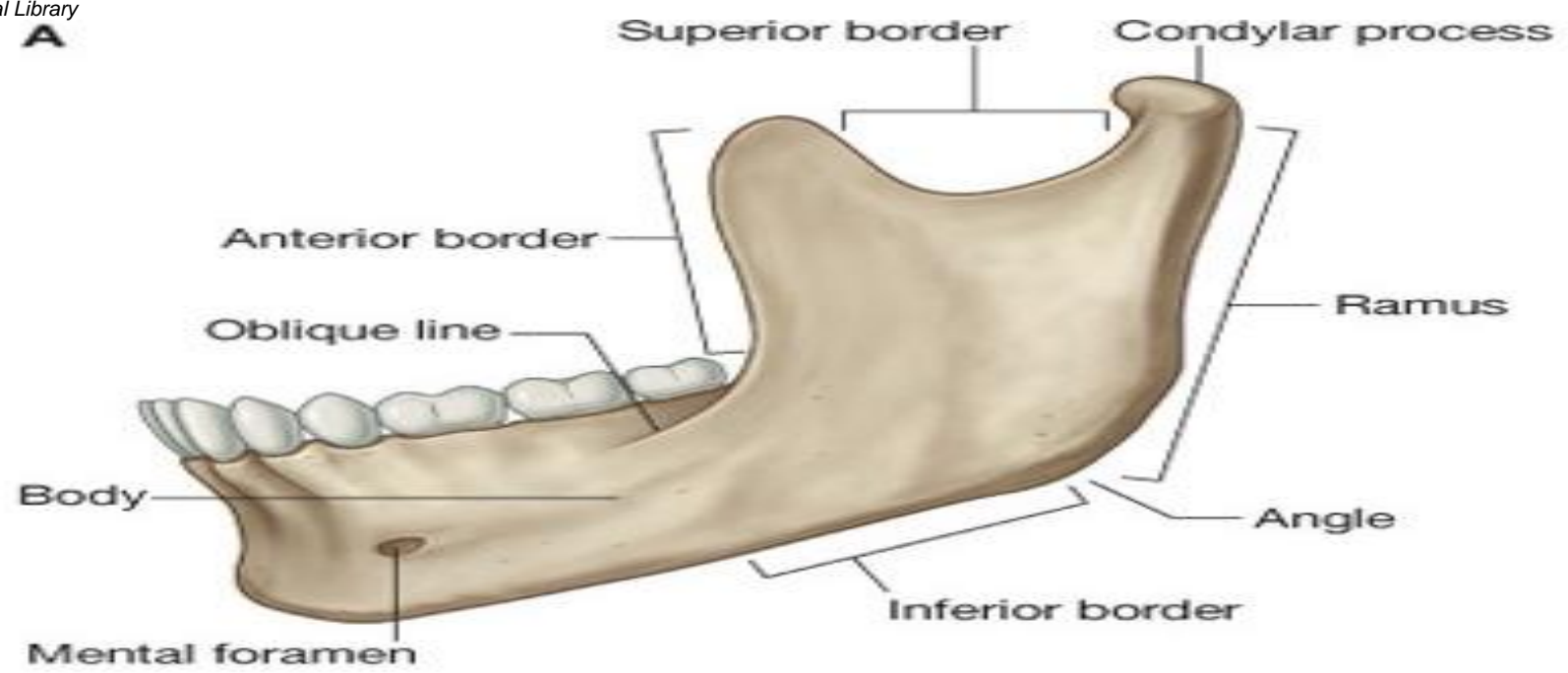




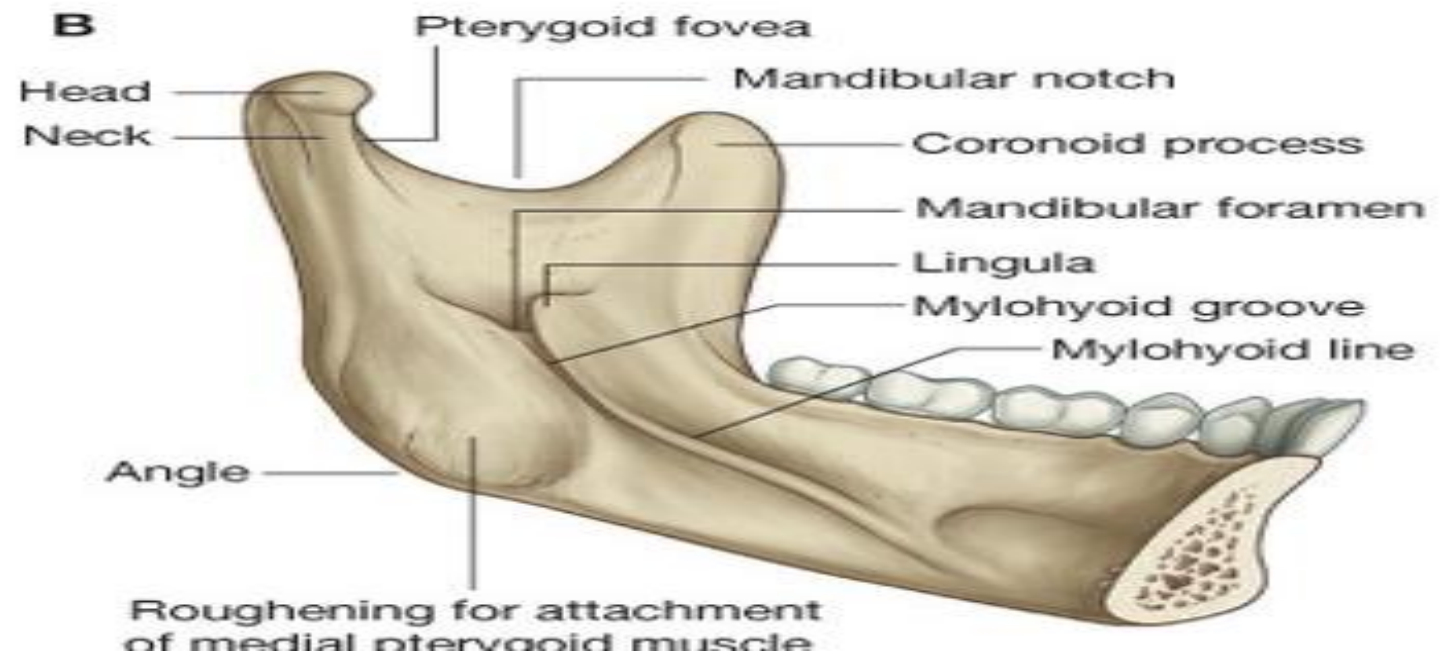




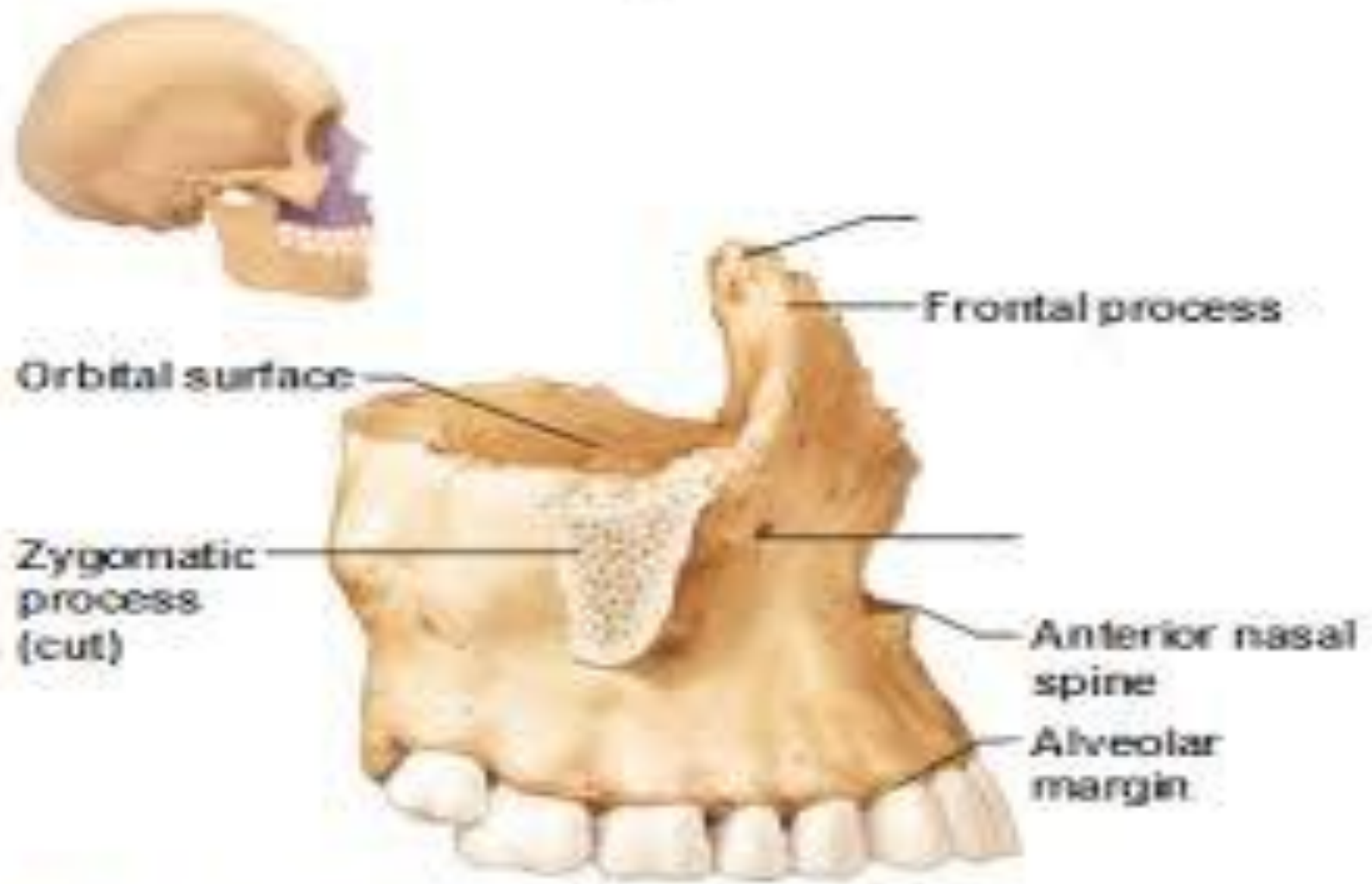
A



B



Maxillary Bones



(b) Maxilla, right lateral view

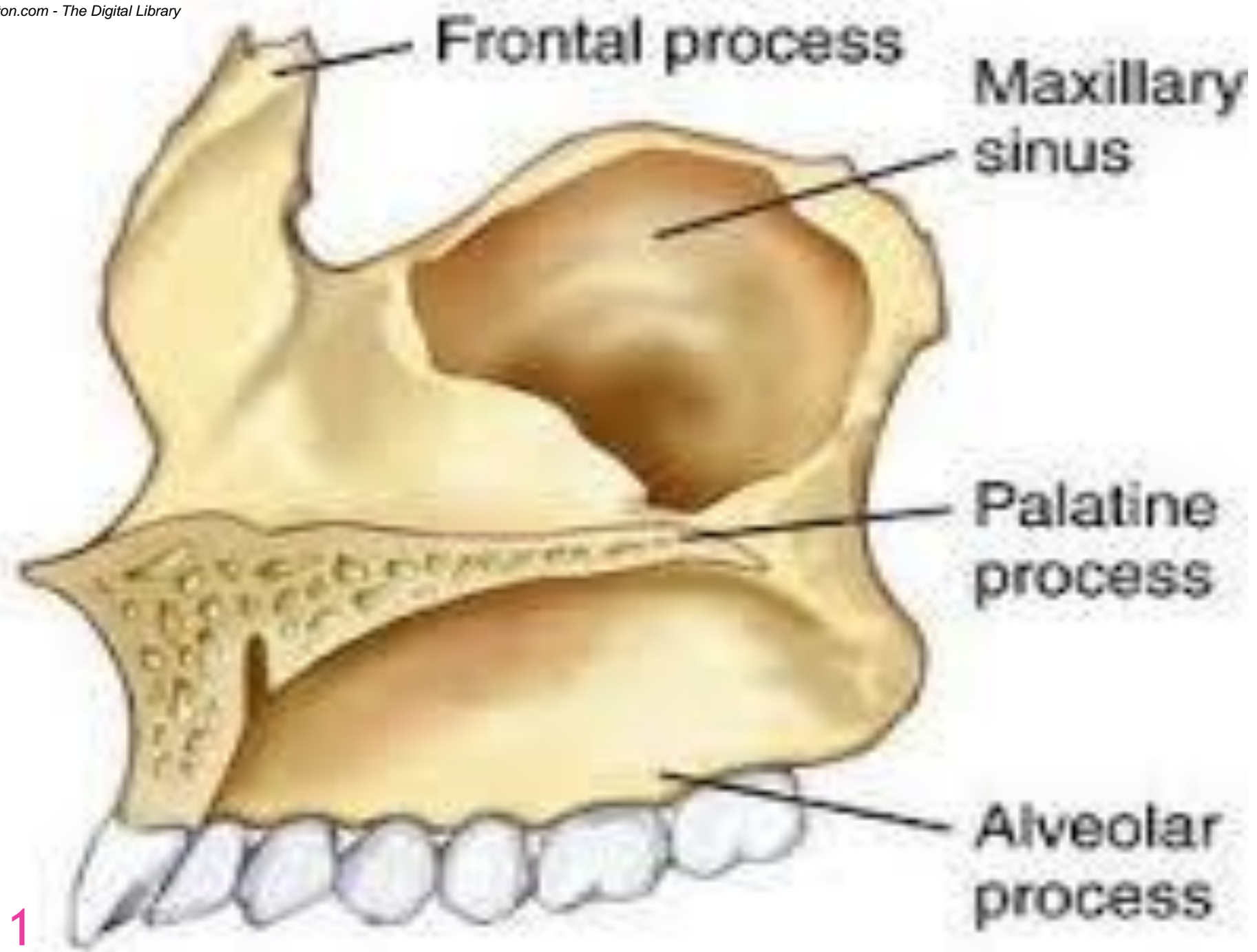
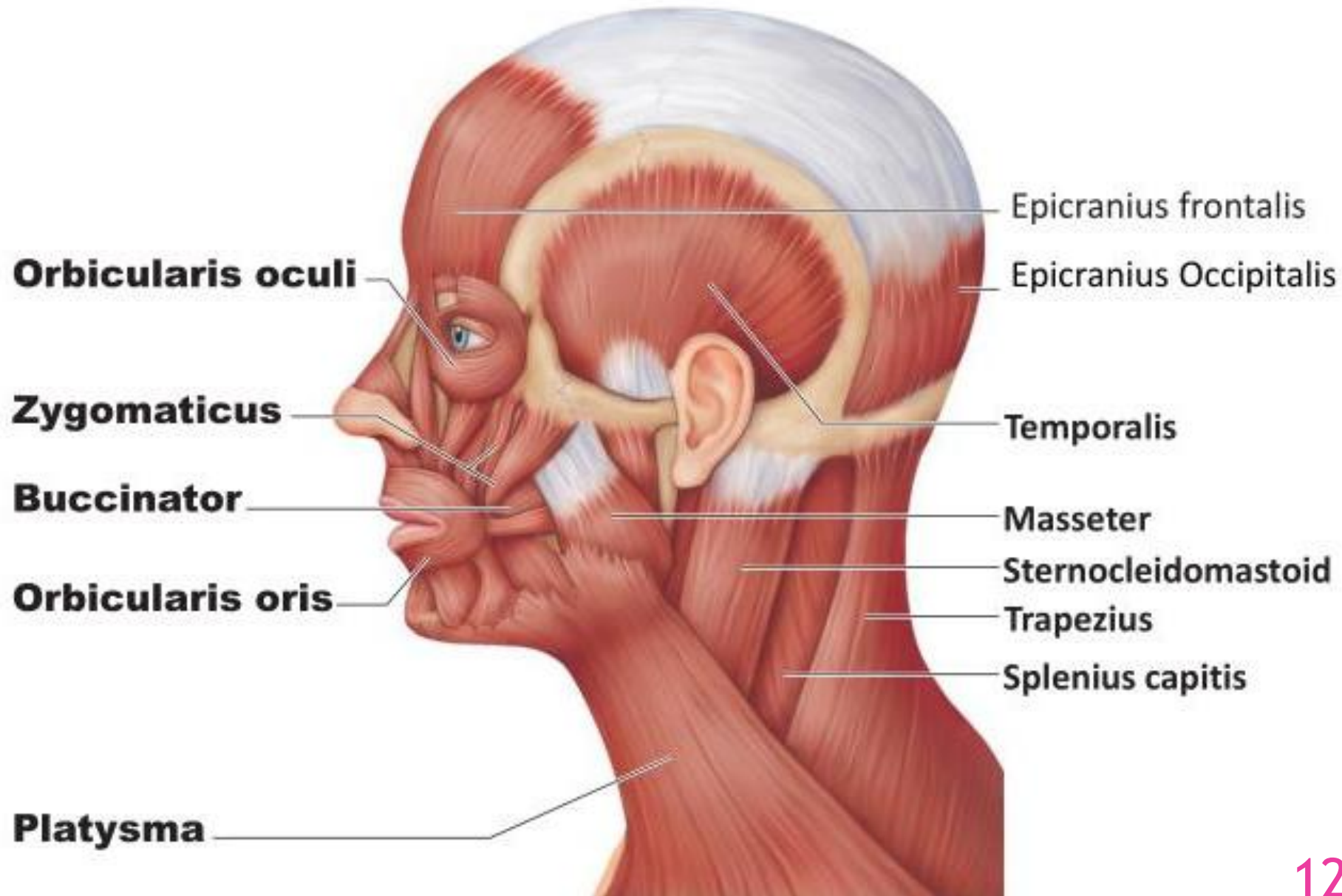
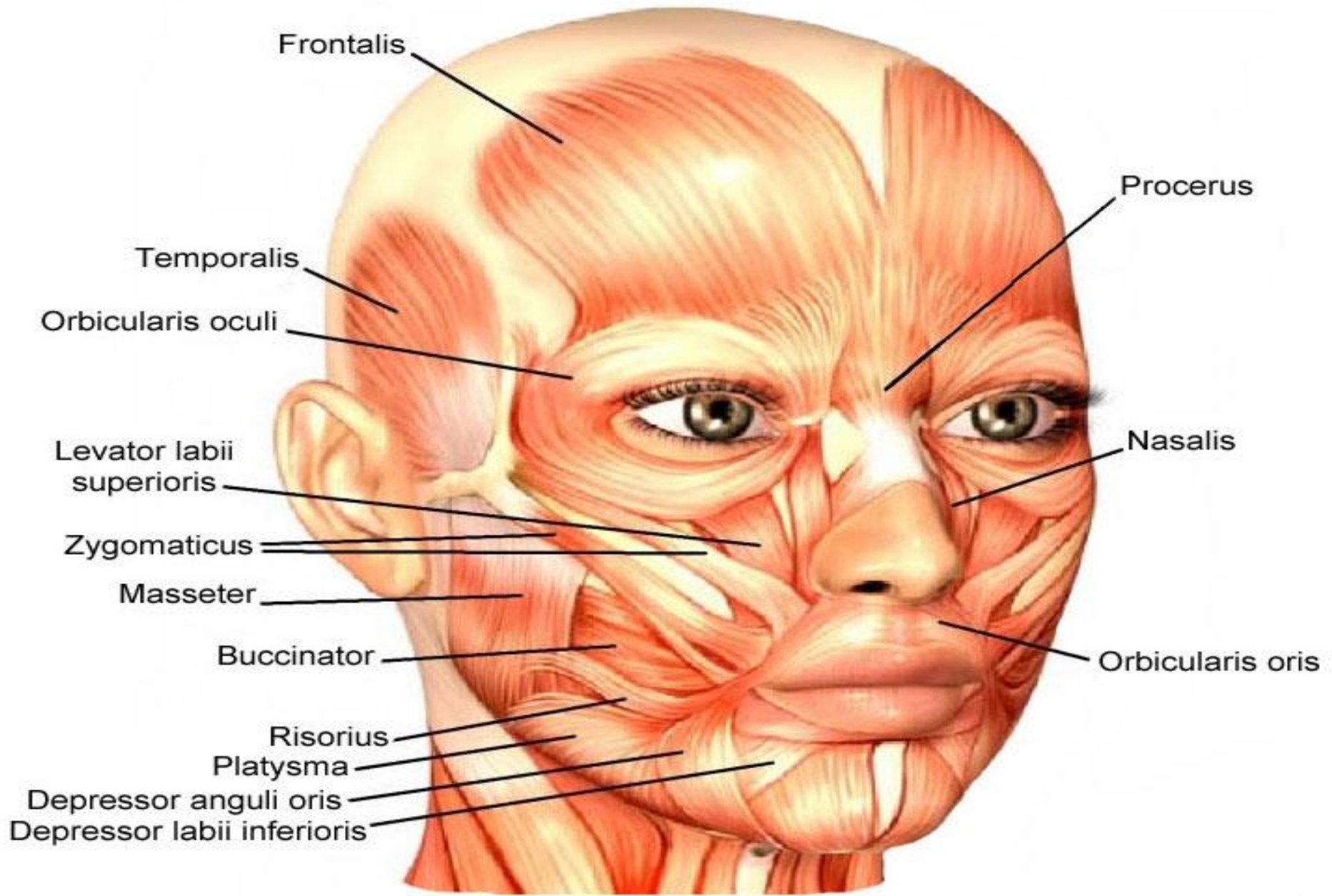


Figure 10.6 Lateral view of muscles of the scalp, face, and neck.





Bones of the Face

- The facial skeleton consists of 14 stationary bones and the mandible.
- These 14 bones form the basic shape of the face, and are responsible for providing attachments for muscles that make the jaw move and control facial expressions.

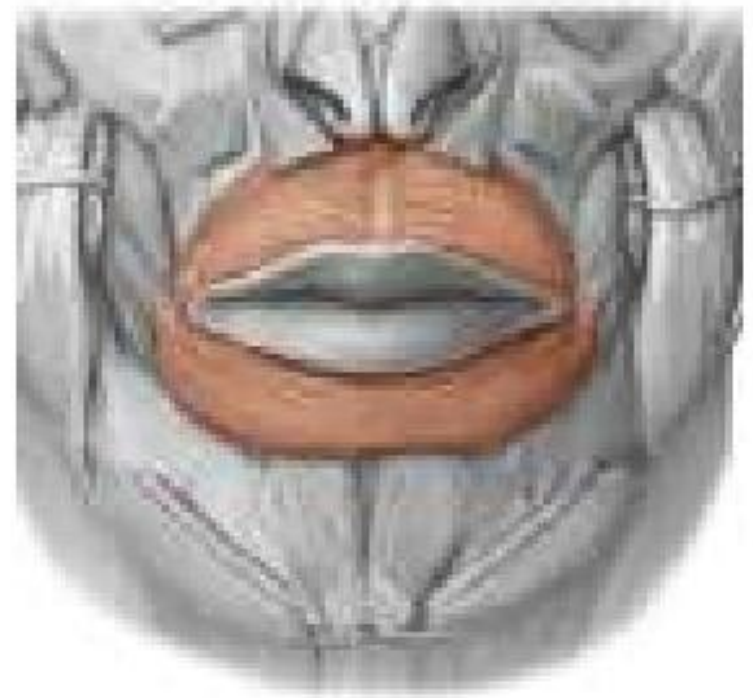
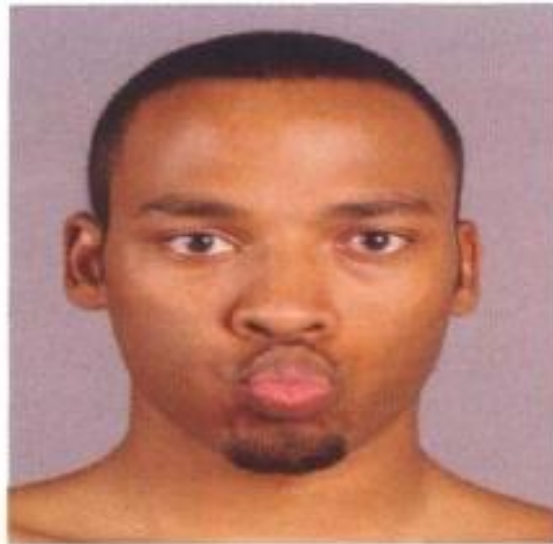Single bones	Paired bones
Vomer	Maxillary
Mandible	Palatine
	Zygomatic
	Lacrimal
	Nasal
	Inferior nasal conchae

Oral group

- The muscles in the oral group move the lips and cheek:
 - Orbicularis oris
 - Buccinator
 - Lower group of oral muscles
 - depressor anguli oris
 - depressor labii inferioris
 - Mentalis
 - Upper group of oral muscles
 - risorius
 - zygomaticus major and zygomaticus minor
 - levator labii superioris
 - levator labii superioris alaeque nasi
 - levator anguli oris

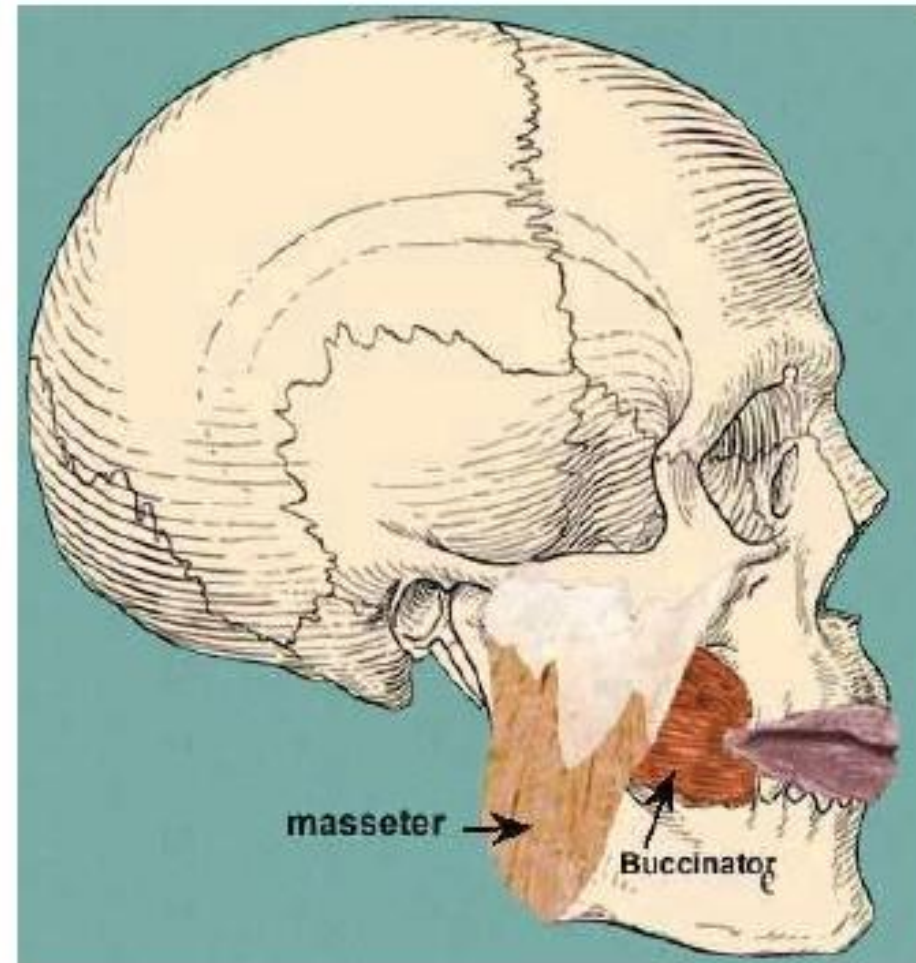
Orbicularis oris

- Origin: from maxilla above incisor teeth
- Insertion: into skin of lip.
- Action: closes the mouth



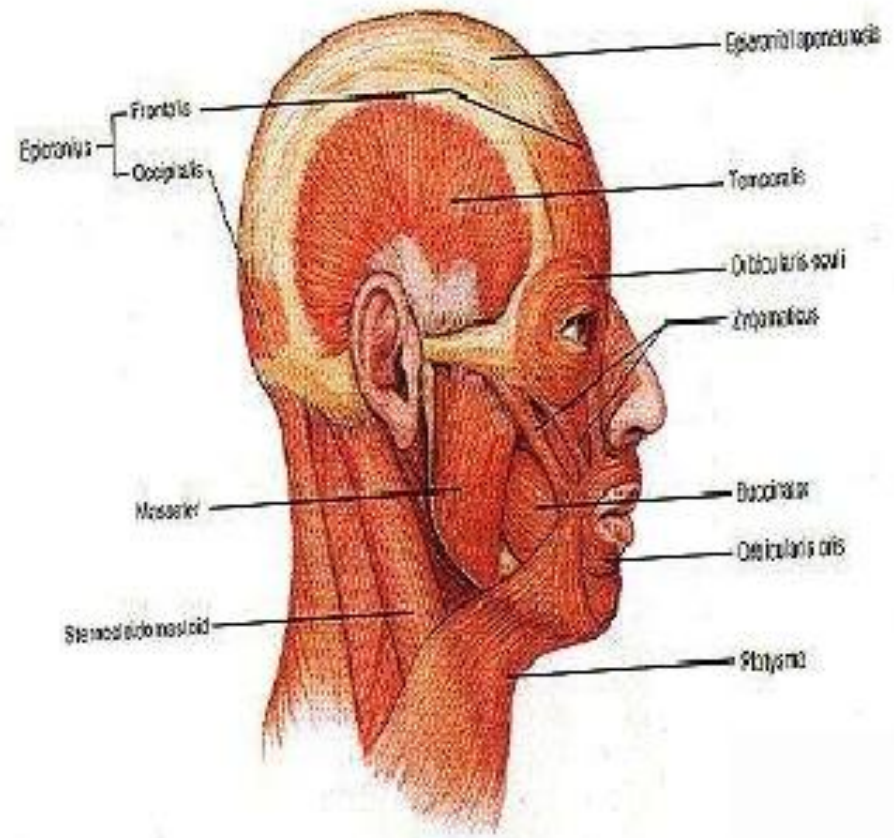
Buccinator

- **Upper fibers**
 - Origin- from maxilla opposite molar teeth
 - Insertion-upper lip
- **Lower fibers**
 - Origin-from mandible opposite molar teeth
 - Insertion-lower lip
- **Middle fibers**
 - Origin –from pterigomandibular raphe
 - Insertion-decussate before passing to lips
- Action- it aids in mastication by prevent accumulation of food in vestibule of mouth. It is used every time air expanding the cheeks is forcefully expelled



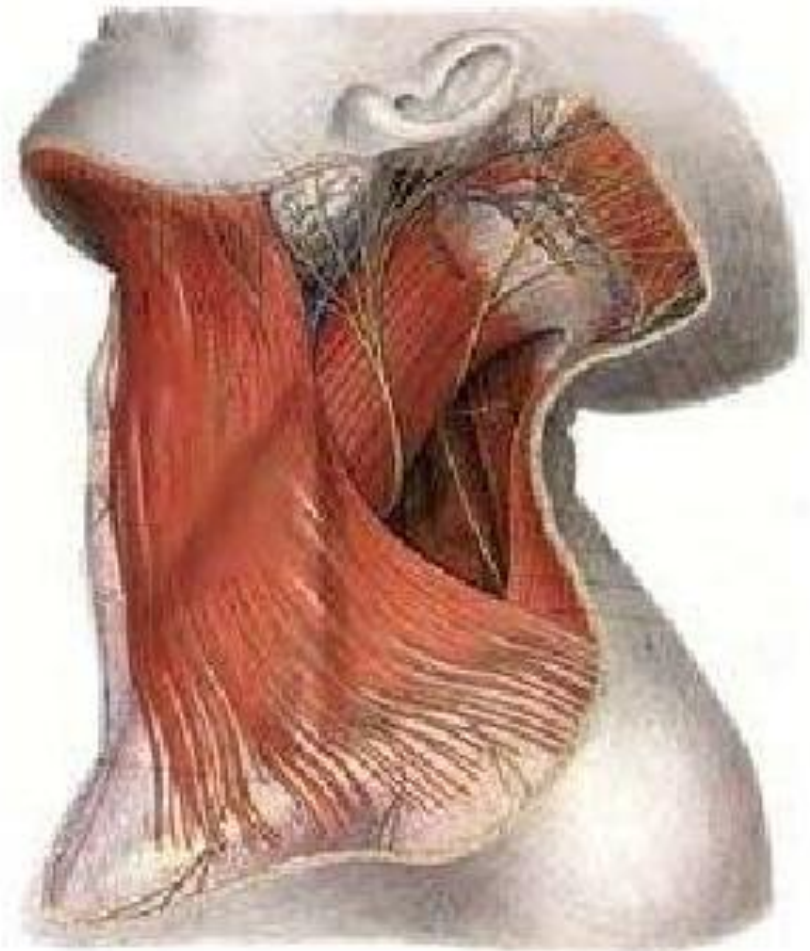
Other muscle groups

- They include:
 - Platysma
 - Auricular (anterior, superior, and posterior auricular muscles)
 - Occipitofrontalis



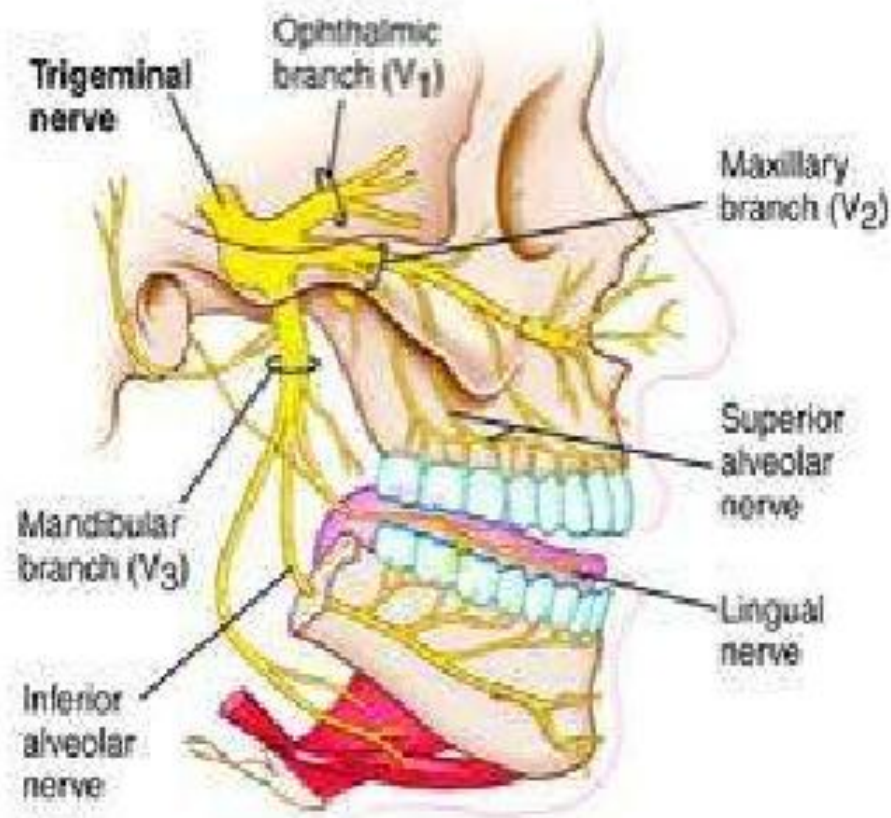
Platysma

- Origin– upper part of pectoral and deltoid fascia
- Insertion– base of mandible, skin of lower face and lip
- Action– releases pressure of skin on the subjacent veins, depress mandible, pulls angle of mouth downwards.

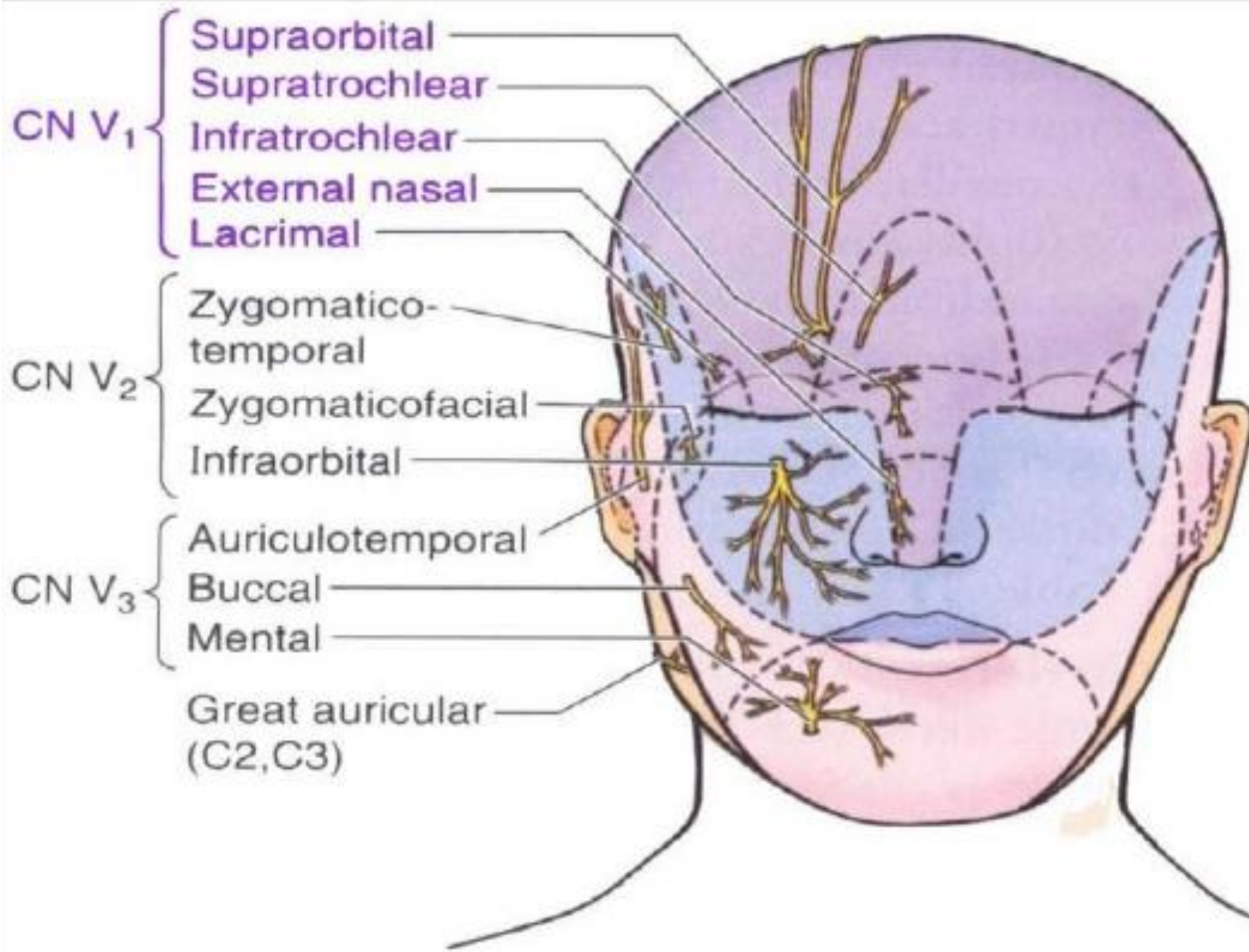


Sensory Nerves of the Face

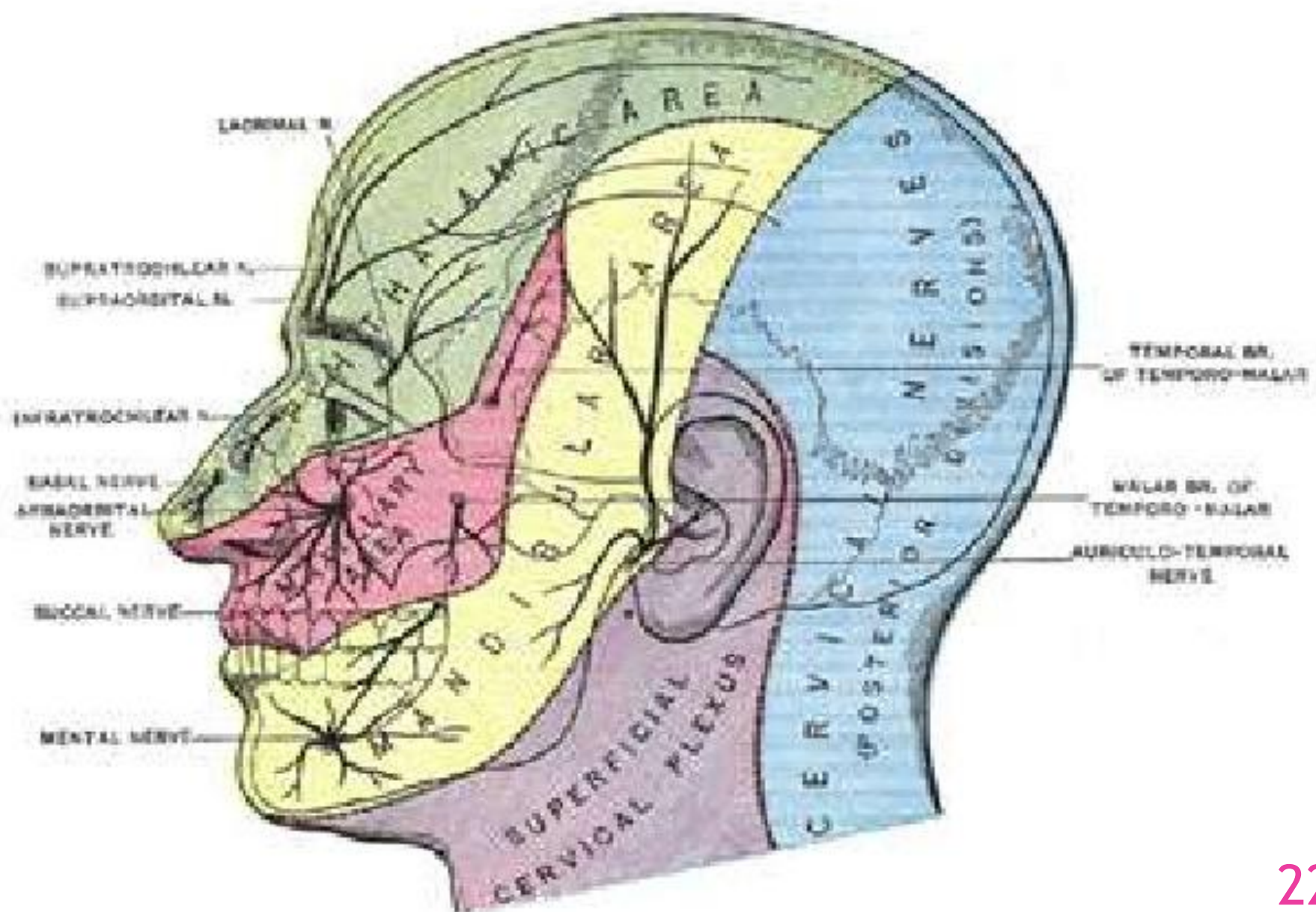
- The skin of the face is supplied by **the trigeminal nerve (V)**, except for the small area over the angle of the mandible and the parotid gland which is supplied by the **great auricular nerve (C2 and 3)**.
- The trigeminal nerve (V) divides into three major **divisions-the ophthalmic (V₁), maxillary (V₂), and mandibular (V₃) nerves**



Sensory Nerves of the Face

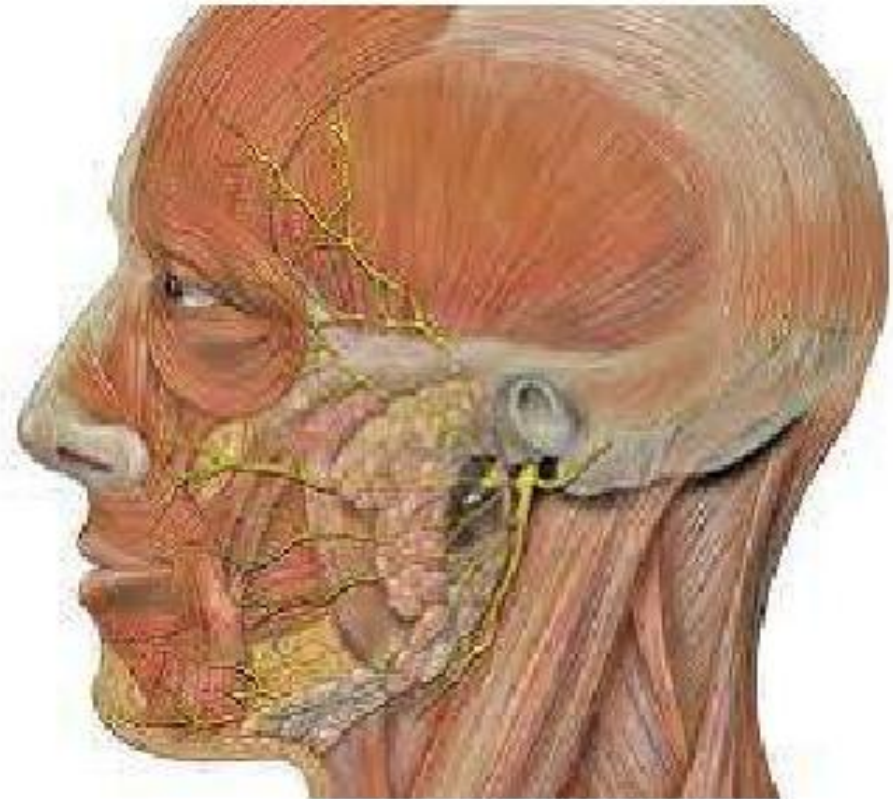


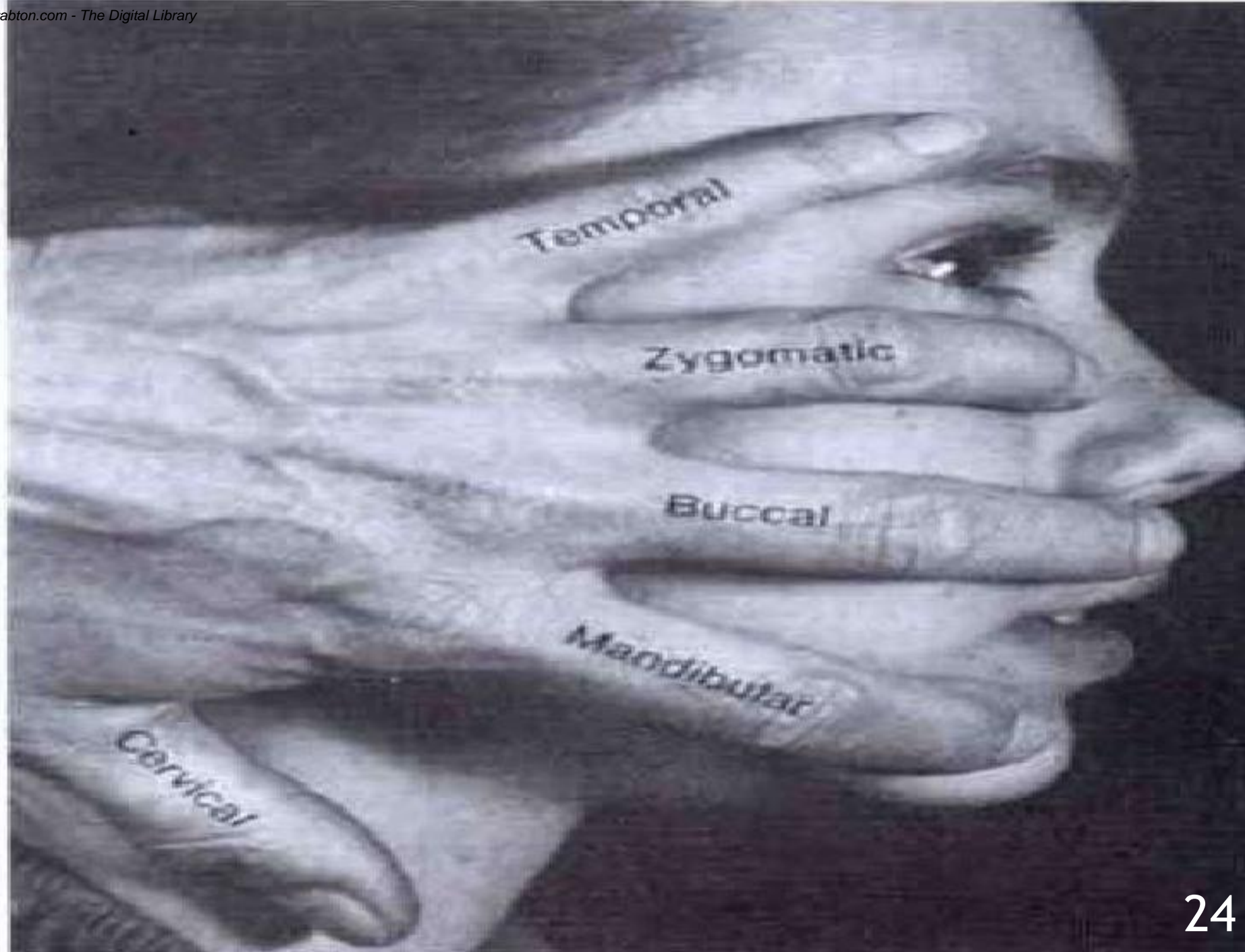
Sensory Nerves of the Face



Motor Nerves of the Face

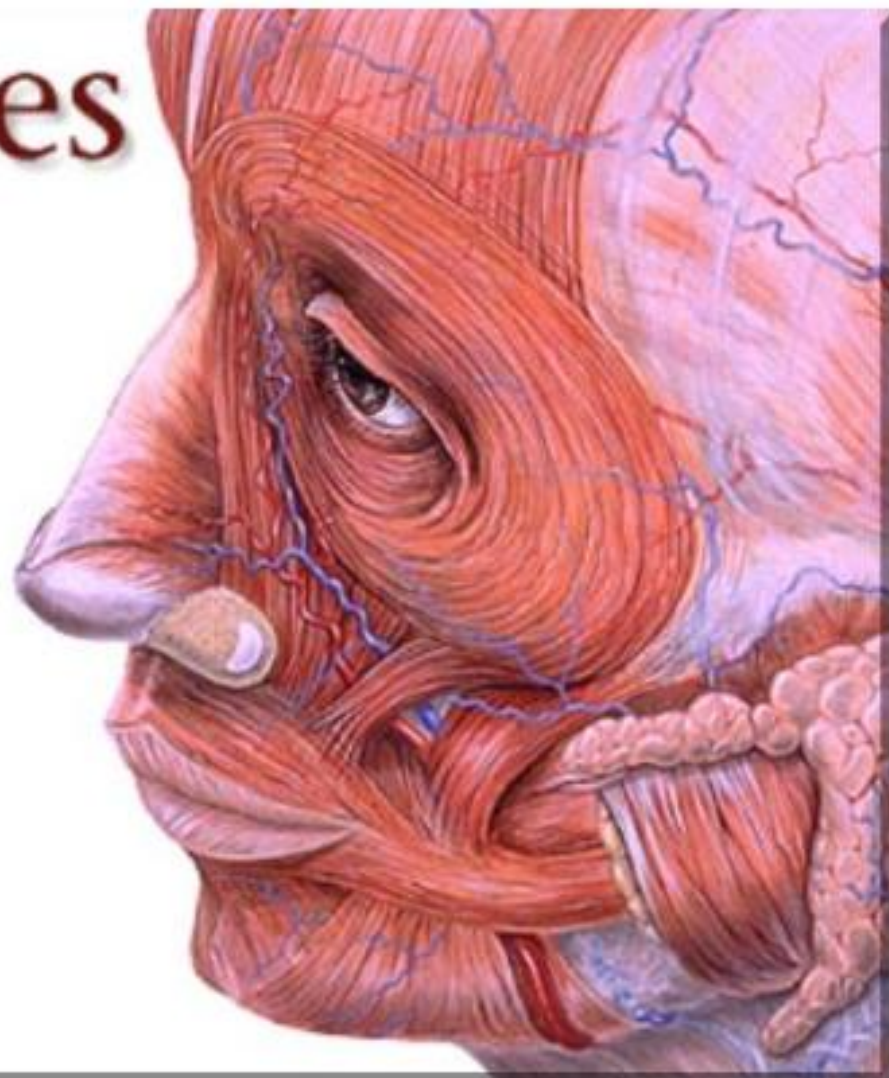
- Motor supply:
 - Facial nerve
- Facial nerve divides into five terminal branches for muscles of facial expression:
 - Temporal
 - Zygomatic
 - Buccal
 - Marginal mandibular
 - Cervical





Cranial Nerves

- I Olfactory
- II Optic
- III Oculomotor
- IV Trochlear
- V Trigeminal
- VI Abducens
- VII Facial
- VIII Vestibulocochlear
- IX Glossopharyngeal
- X Vagus
- XI Accessory
- XII Hypoglossal



I. Olfactory Nerve

❖ Component: Sensory

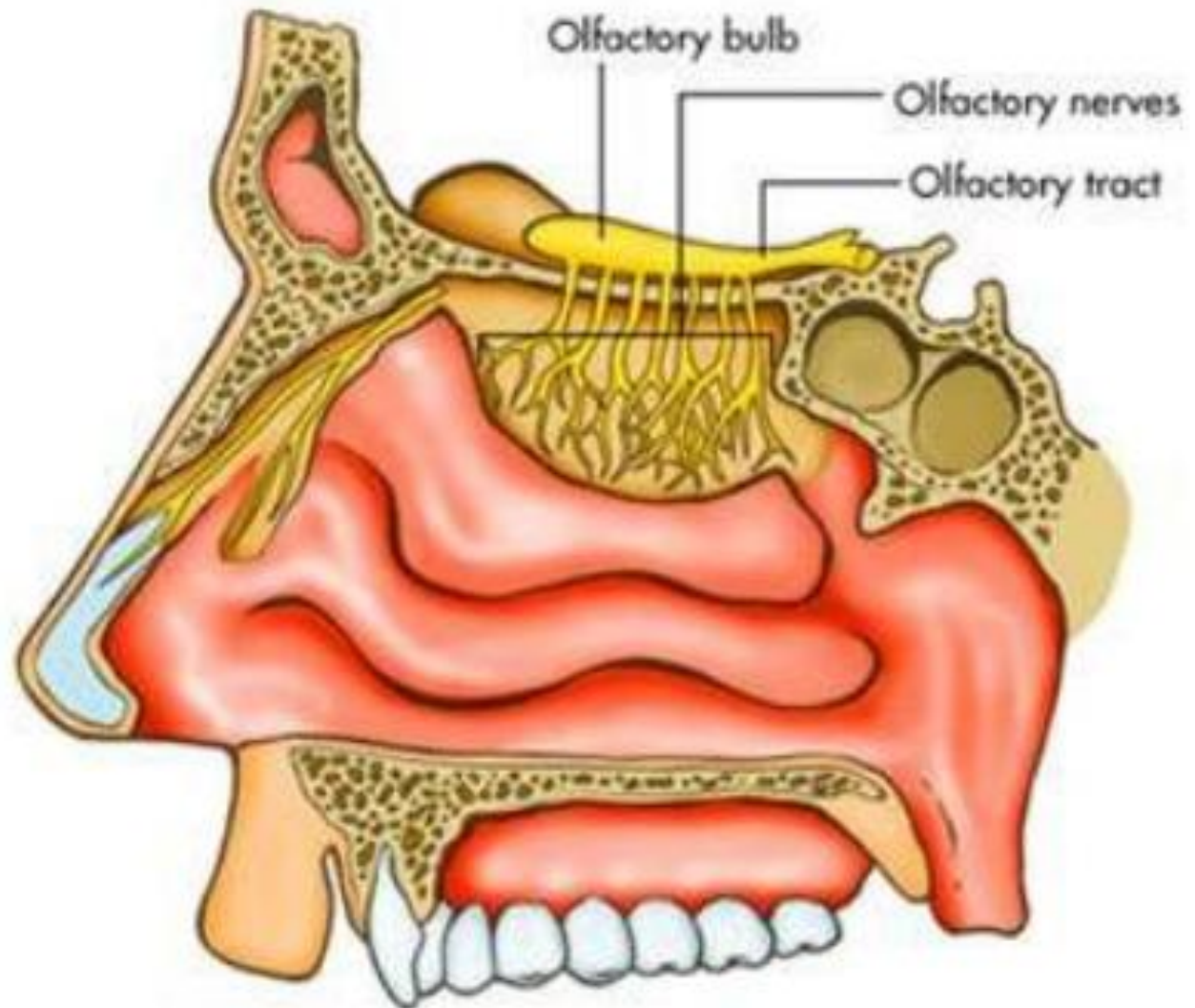
❖ Function: Smell

❖ Origin: Olfactory receptor nerve cells

❖ Opening to the Skull: Openings in cribriform plate of ethmoid



Olfactory Nerve



OPTIC NERVE

»» Cranial Nerve II

II. Optic Nerve

Component: Sensory

Function: Vision

Origin: Back of the eyeball

Opening to the Skull: Optic Canal



OCCULOMOTOR NERVE

»» Cranial Nerve III

III. Oculomotor Nerve

- Component: Motor

- Function:

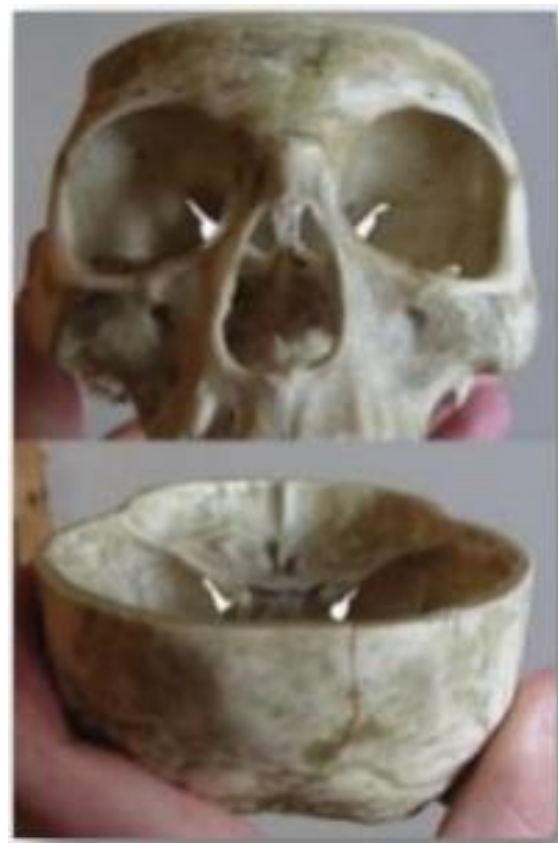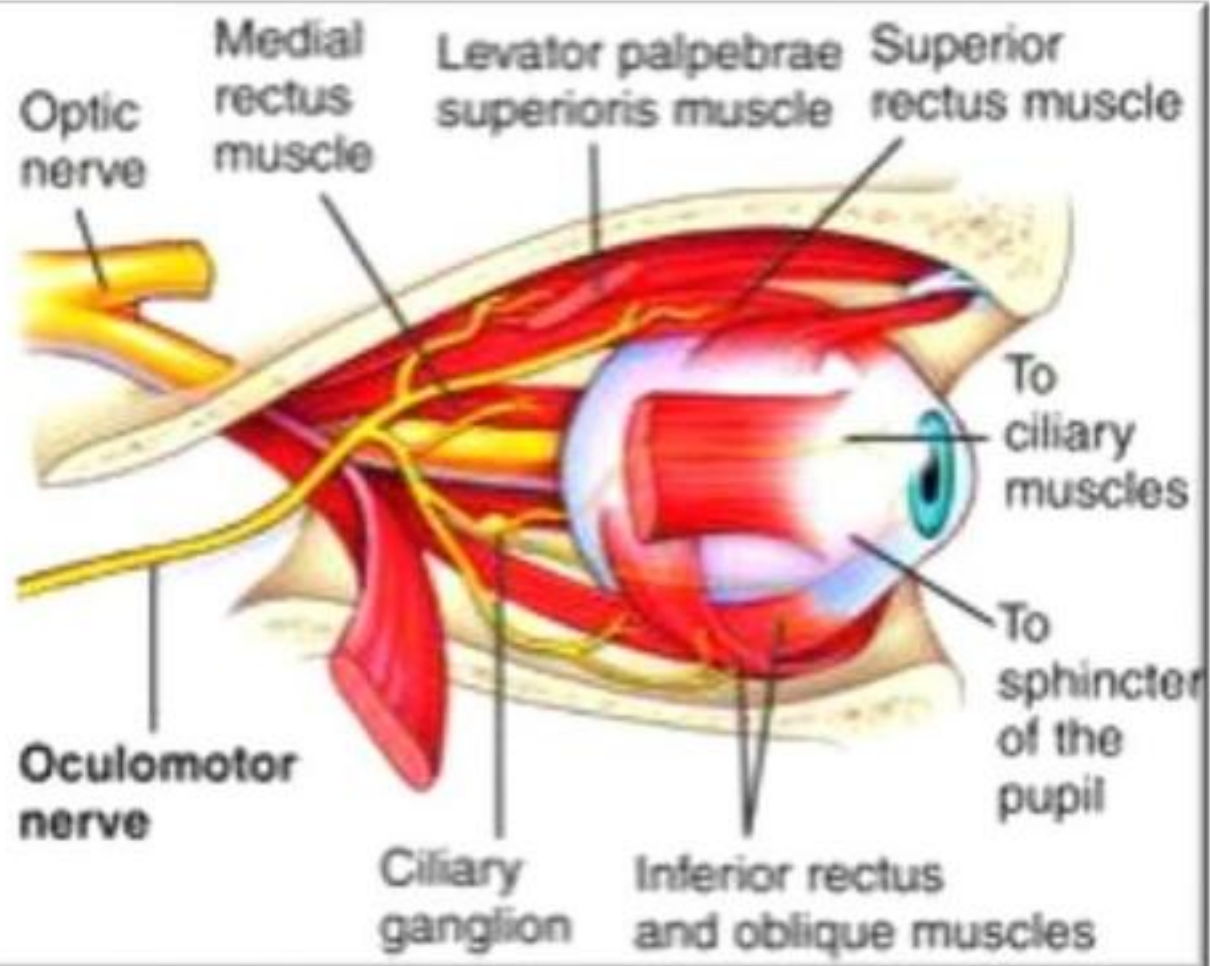
- Raises upper eyelid
- Turns eyeball upward, downward and medially
- Constricts pupil
- Accommodates the eye



- Origin: Anterior surface of the midbrain

- Opening to the Skull: Superior orbital fissure

III. Oculomotor Nerve

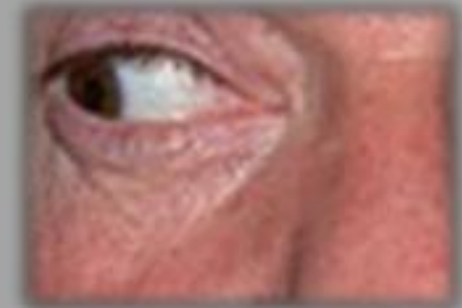

TROCHLEAR NERVE

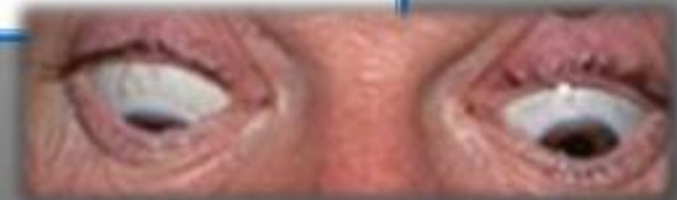»» Cranial Nerve IV

IV. Trochlear Nerve

✓ Component: **Motor**



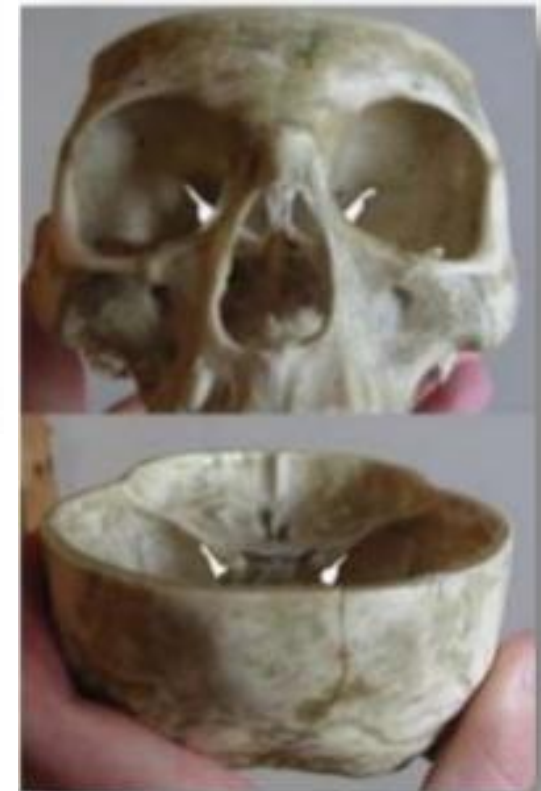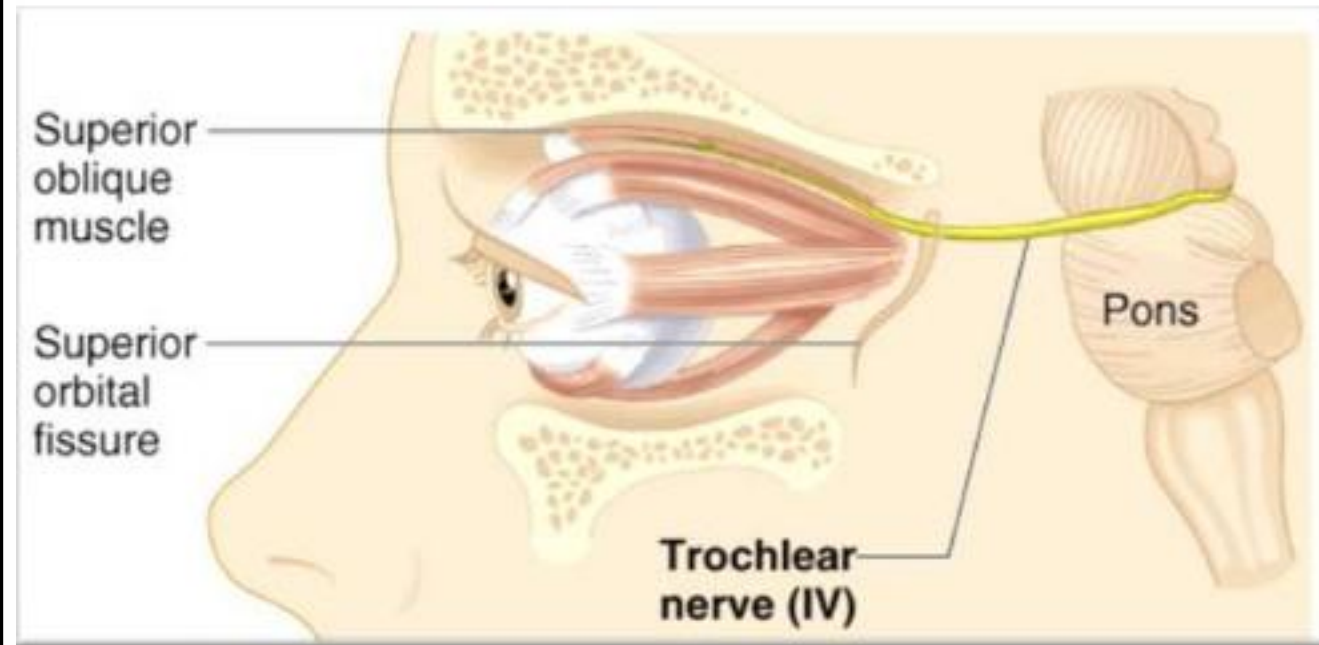
✓ Function: **Assisting in turning eyeball downward and laterally**



✓ Origin: **Posterior surface of the midbrain**

✓ Opening to the Skull: **Superior orbital fissure**

IV. Trochlear Nerve



TRIGEMINAL NERVE

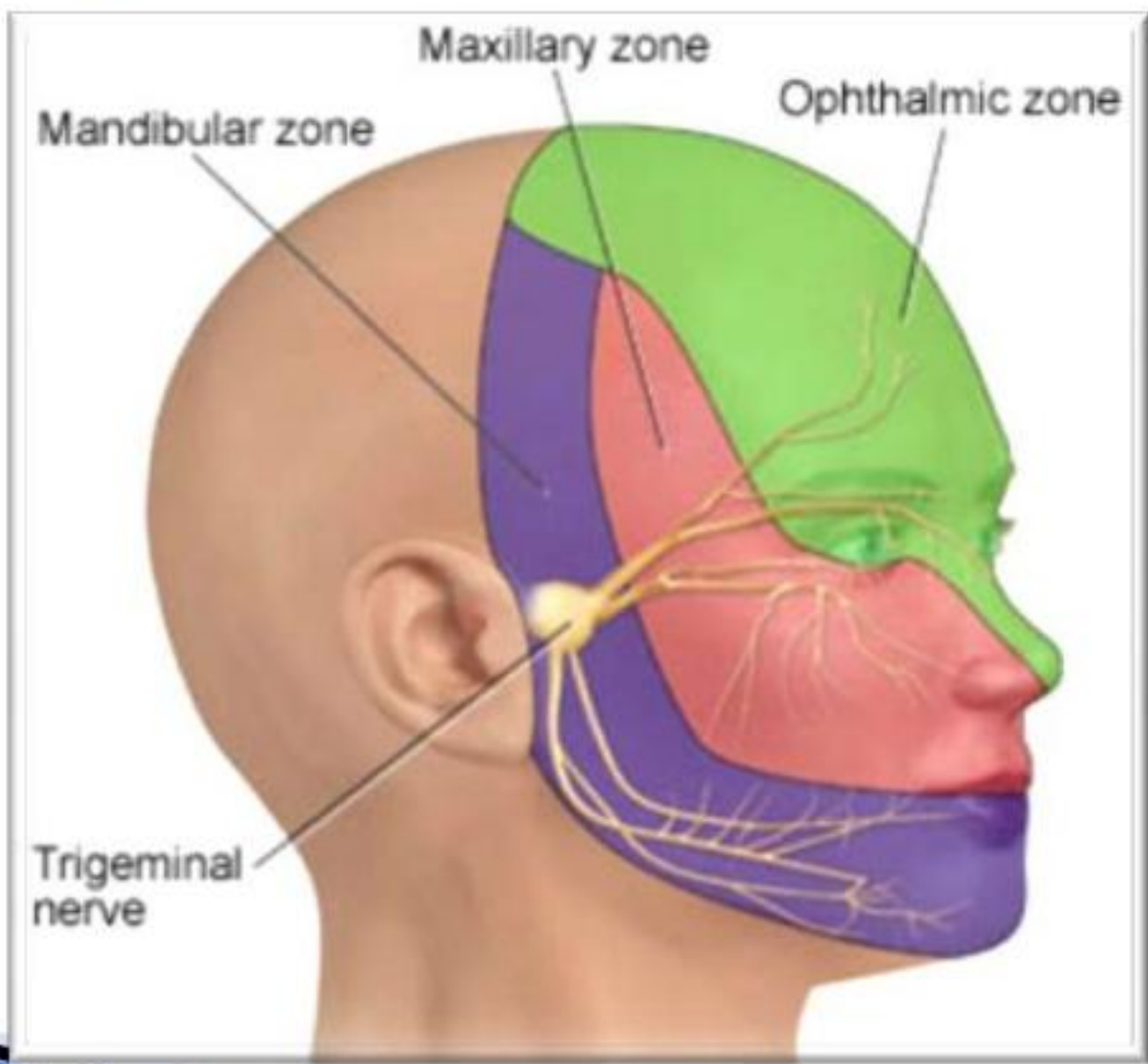
»» Cranial Nerve V

V1. Ophthalmic Nerve

V2. Maxillary Nerve

V3. Mandibular Nerve

V. Trigeminal Nerve



V1. Ophthalmic Nerve

❖ Component: Sensory

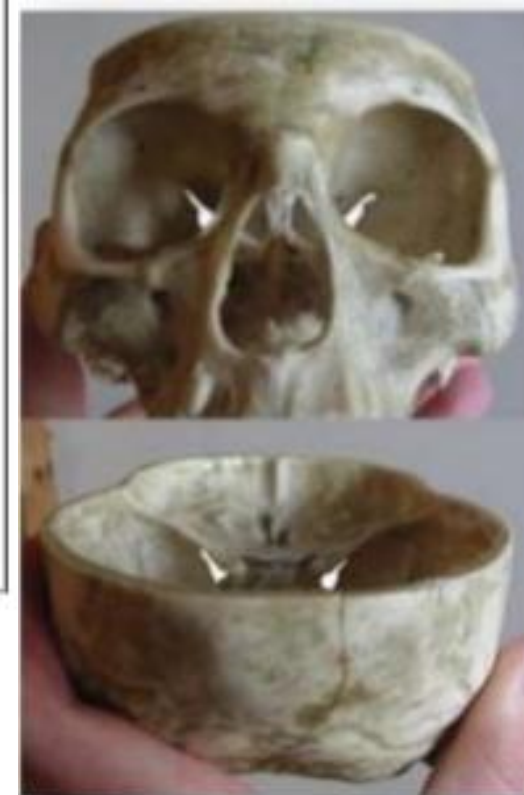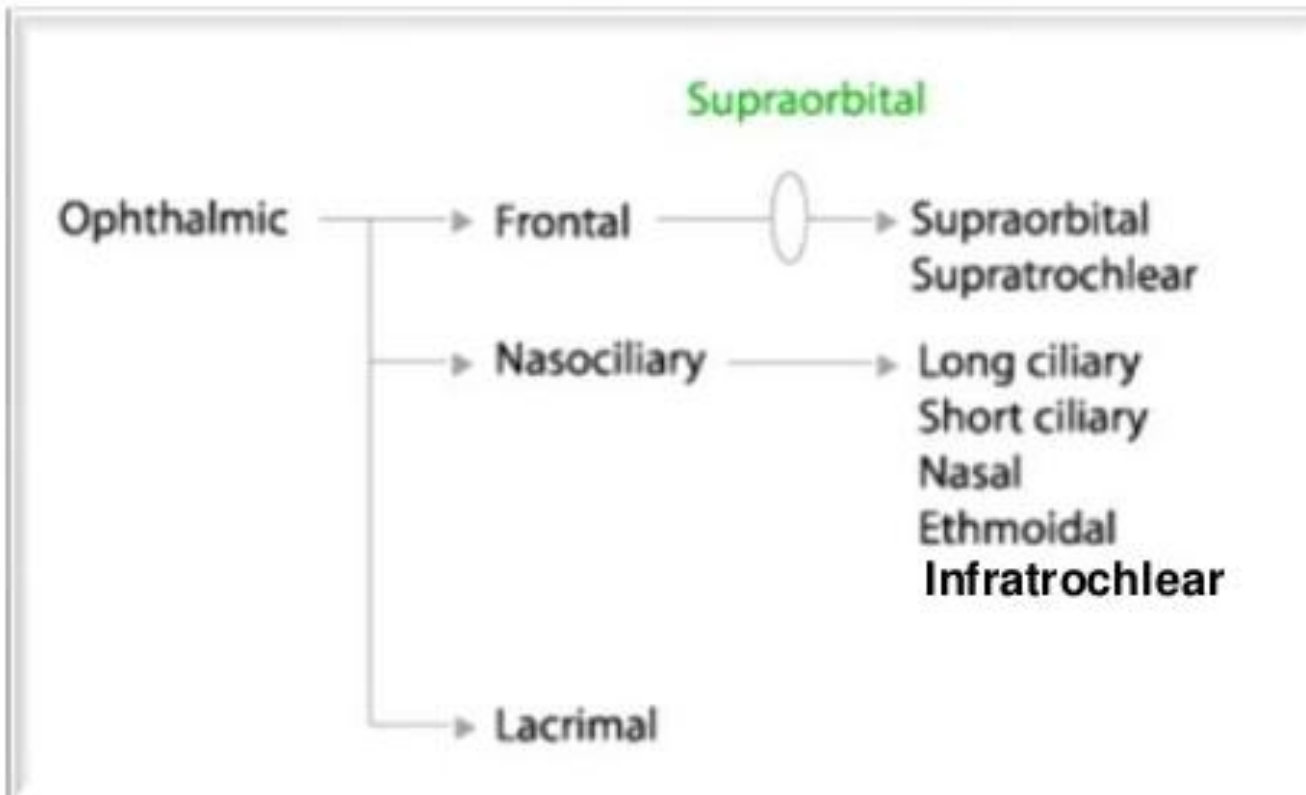
❖ Function:

- ❖ Cornea
- ❖ Skin of forehead
- ❖ Scalp
- ❖ Eyelids and nose
- ❖ Mucous membranes of paranasal sinuses and nasal cavity

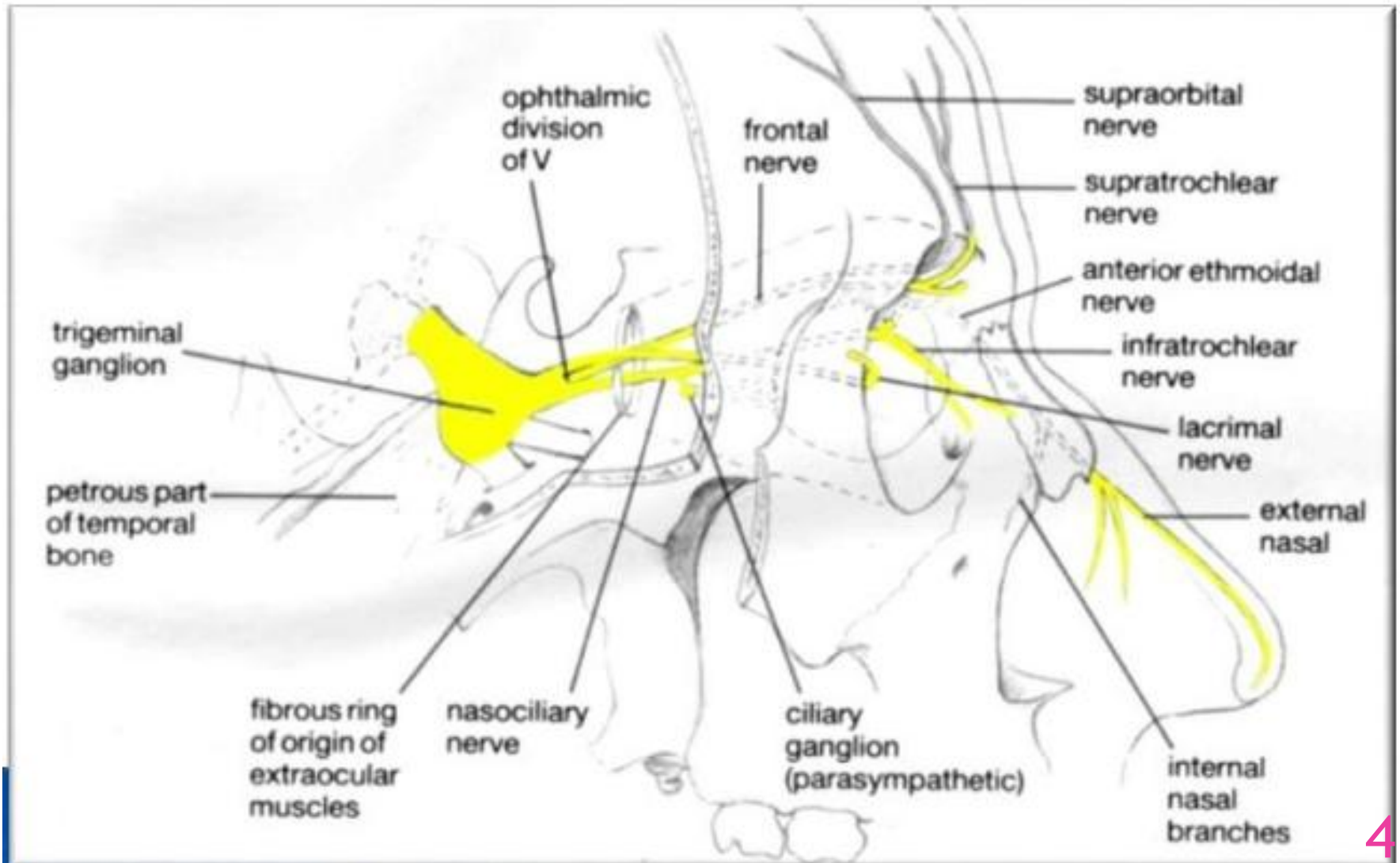
❖ Origin: Anterior aspect of the pons

❖ Opening to the Skull: Superior orbital fissure

V1. Ophthalmic Nerve



V1. Ophthalmic Nerve



V2. Maxillary Nerve

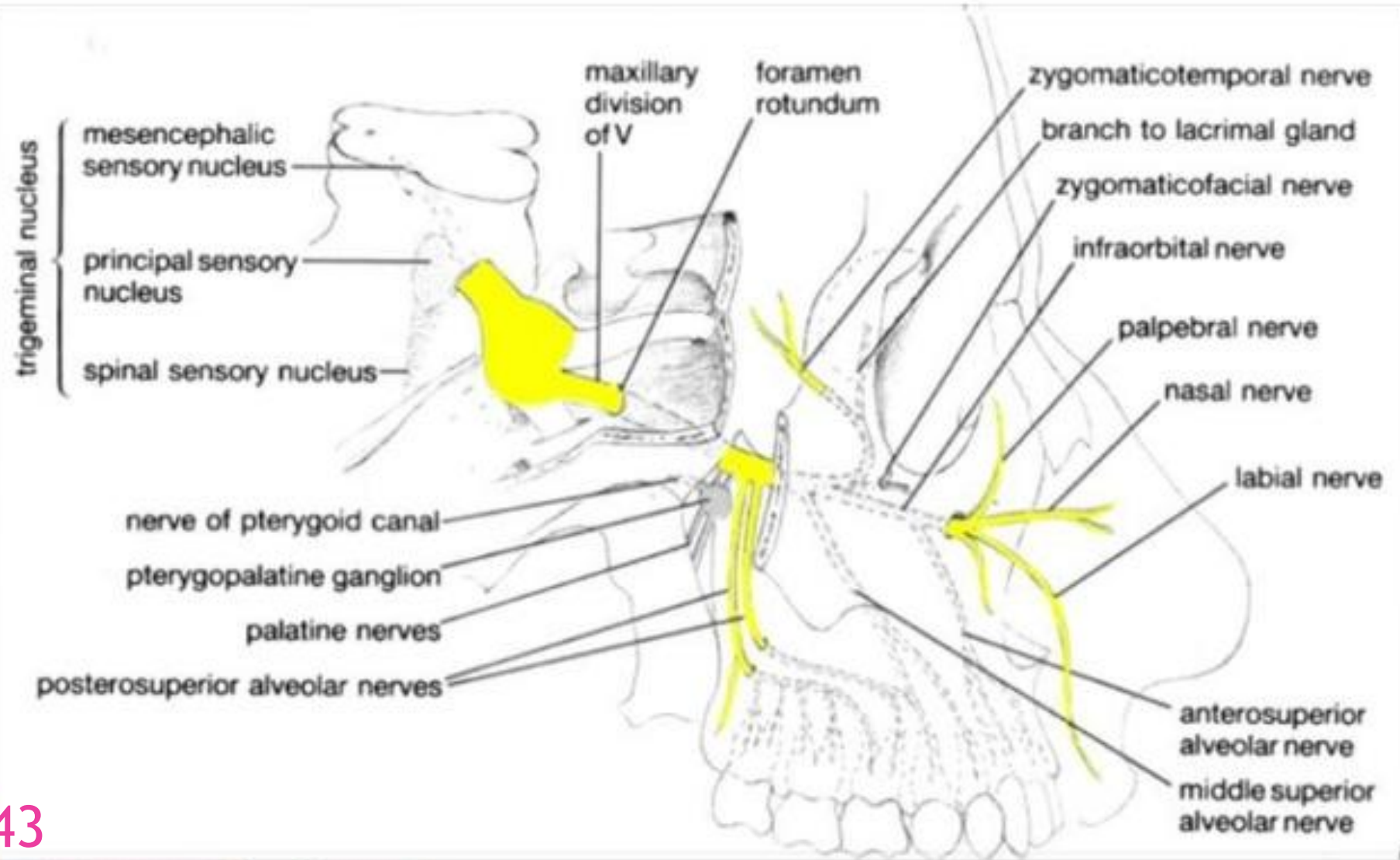
- Component: Sensory

- Function:
 - Skin of the face over maxilla
 - Teeth of the upper jaw
 - Mucous membrane of the nose, the maxillary sinus and palate

- Origin: Anterior aspect of the pons

- Opening to the Skull: Foramen ovale

V2. Maxillary Nerve



V3. Mandibular Nerve

- Component: a. Motor

- Function:
 - Muscles of mastication
 - Mylohyoid
 - Anterior belly of digastric
 - Tensor veli palatine
 - Tensor tympani

- Origin: Anterior aspect of the pons

- Opening to the Skull: Foramen Rotundum

V3. Mandibular Nerve

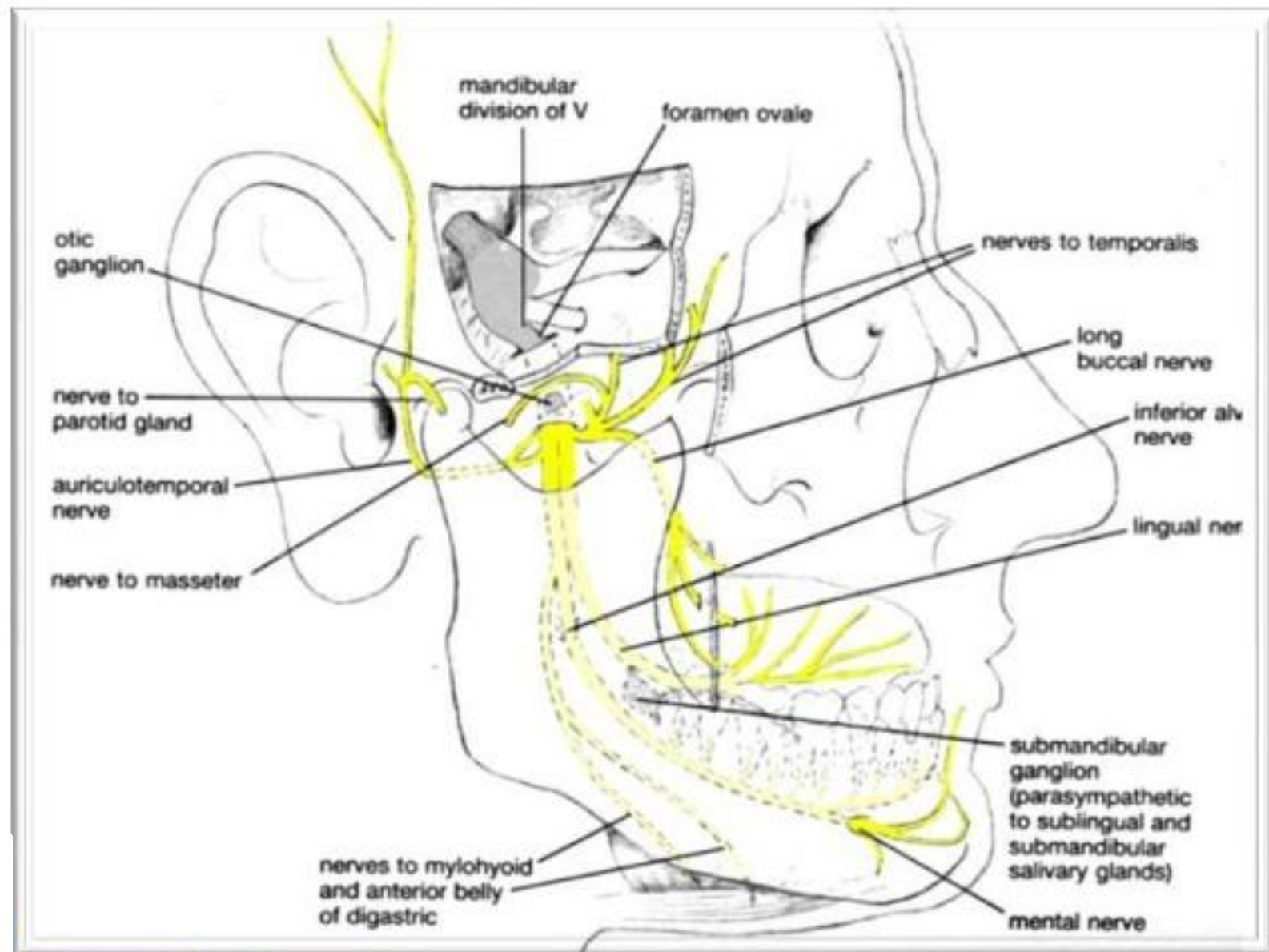
- Component: b. Sensory

- Function:
 - Skin of cheek
 - Skin over mandible and side of head
 - Teeth of lower jaw and TMJ
 - Mucous membrane of mouth and anterior part of tongue

- Origin: Anterior aspect of the pons

- Opening to the Skull: Foramen Rotundum

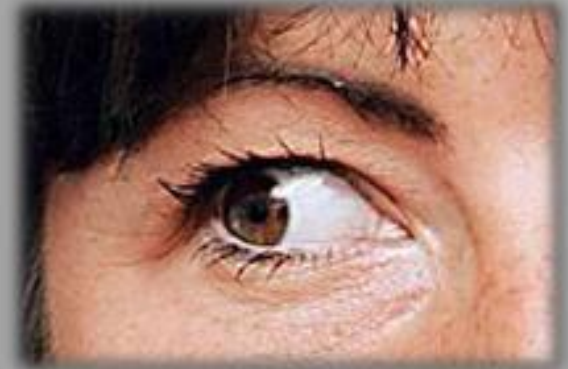V3. Mandibular Nerve



ABDUCENT NERVE

»» Cranial Nerve VI

VI. Abducent Nerve



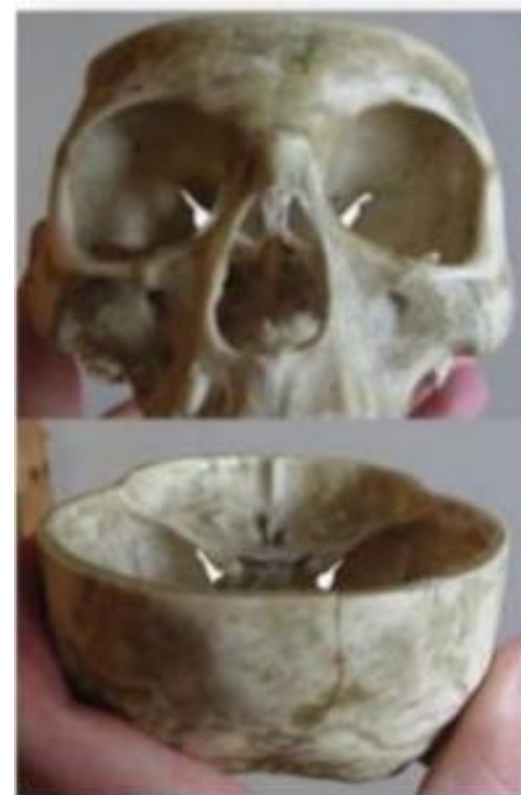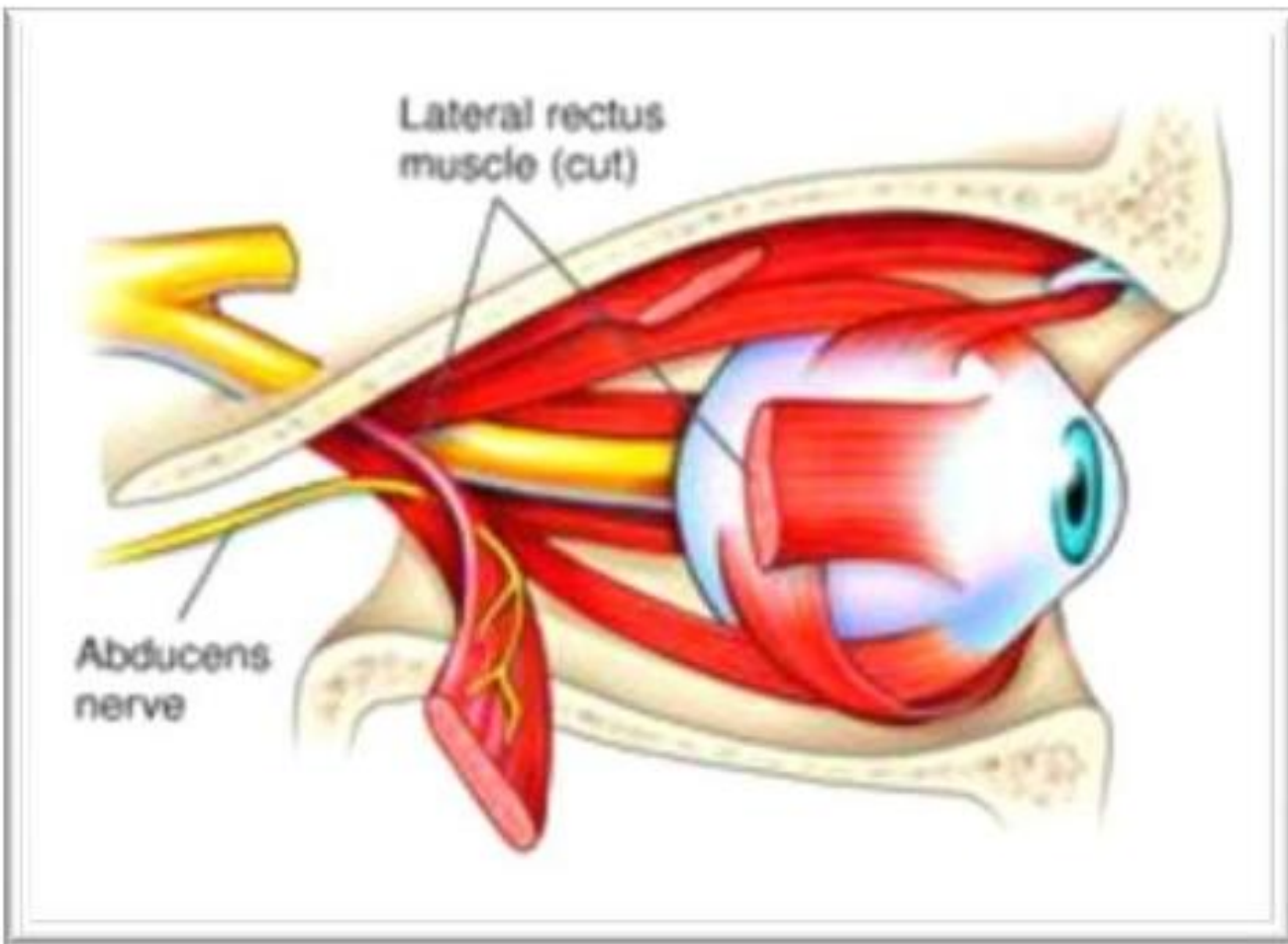
✓ Component: **Motor**

✓ Function: **Lateral rectus muscle turns eyeball laterally**

✓ Origin: **Medulla oblongata**

✓ Opening to the Skull: **Superior orbital fissure**

VI. Abducent Nerve



FACIAL NERVE

»» Cranial Nerve VII

VII. Facial Nerve

☐ Component: **Mixed**

☐ Function:

Motor

- muscles of the face and scalp
- Stapedius muscle
- Posterior belly of digastric
- Stylohyoid muscles

☐ Function:

Sensory

- Taste from ant. 2/3 of tongue, from the floor of the mouth and palate

VII. Facial Nerve

❑ Function:

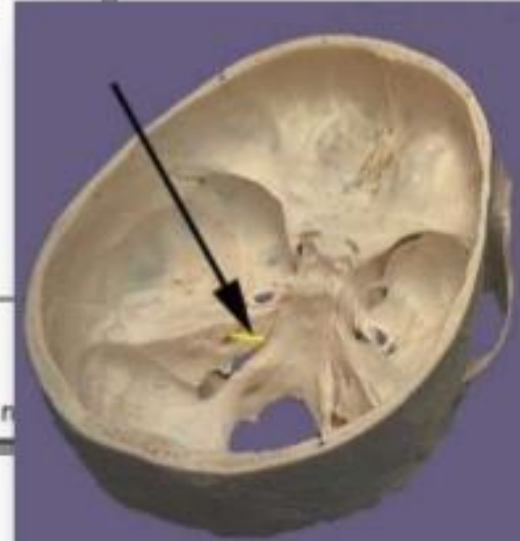
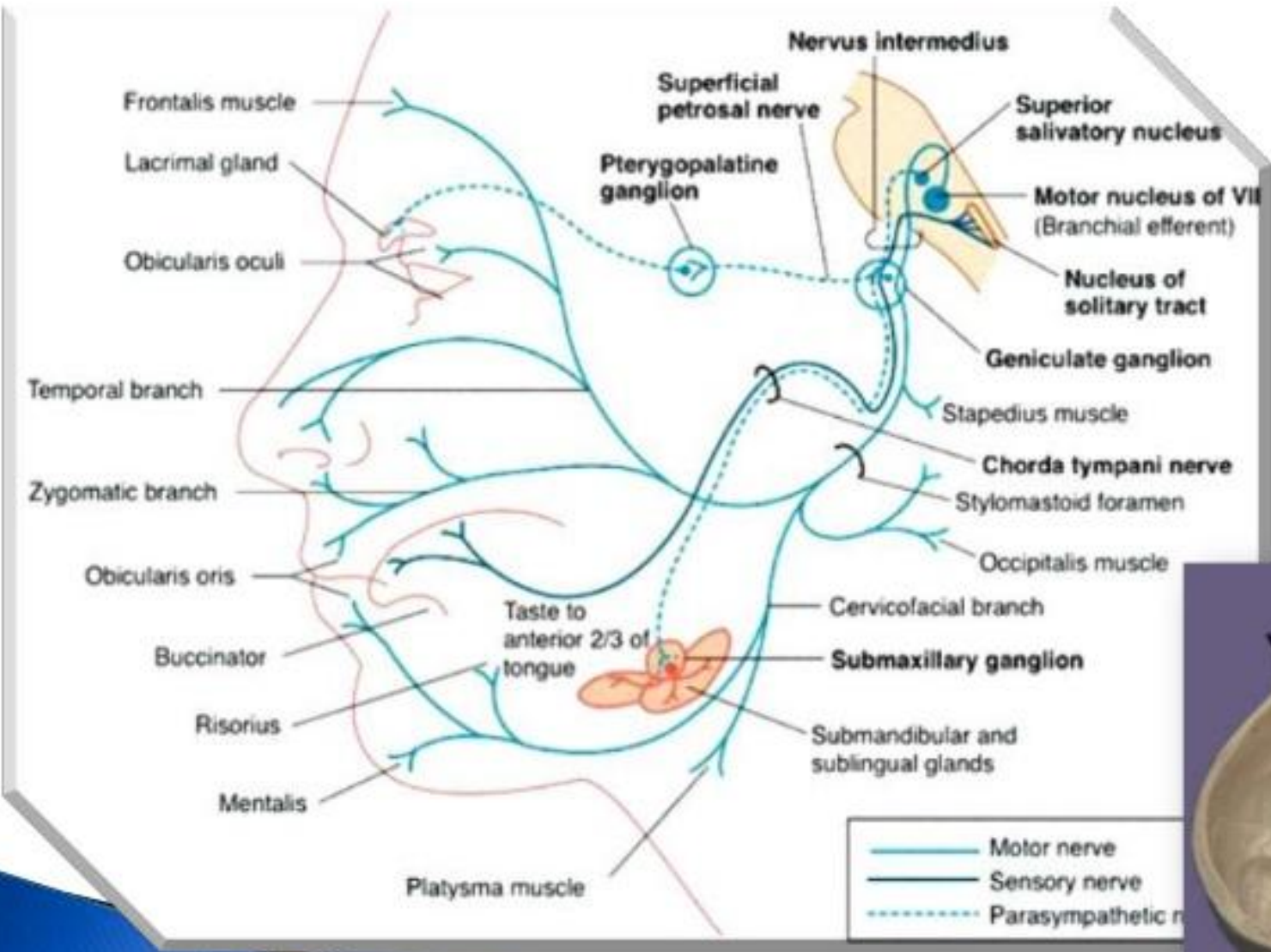
Secretomotor

- Submandibular and sublingual salivary glands
- Lacrimal gland
- Glands of nose and palate

❑ Origin: Medulla oblongata

❑ Opening to the Skull: internal acoustic meatus, facial canal, stylomastoid foramen

VII. Facial Nerve



VESTIBULOCOCHLEAR NERVE

»» Cranial Nerve VIII

*Aka Auditory / Acoustic Nerve

VIII. Vestibulocochlear Nerve

- Component: Sensory

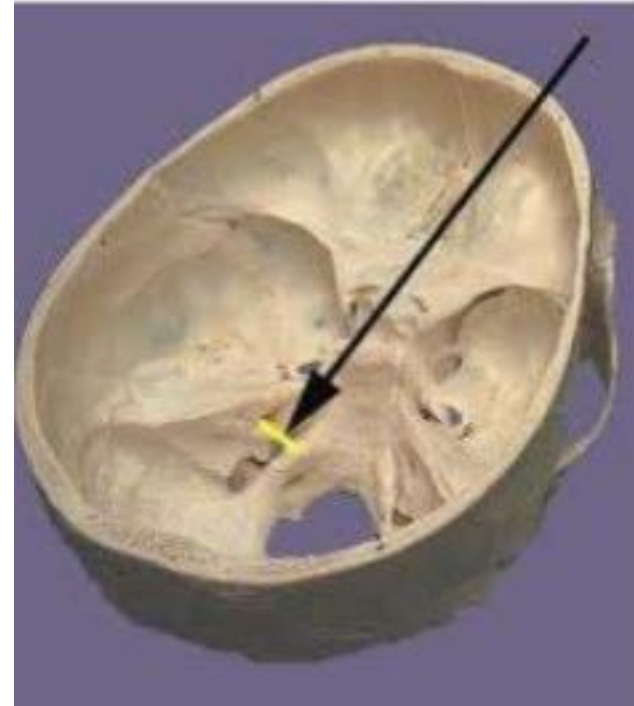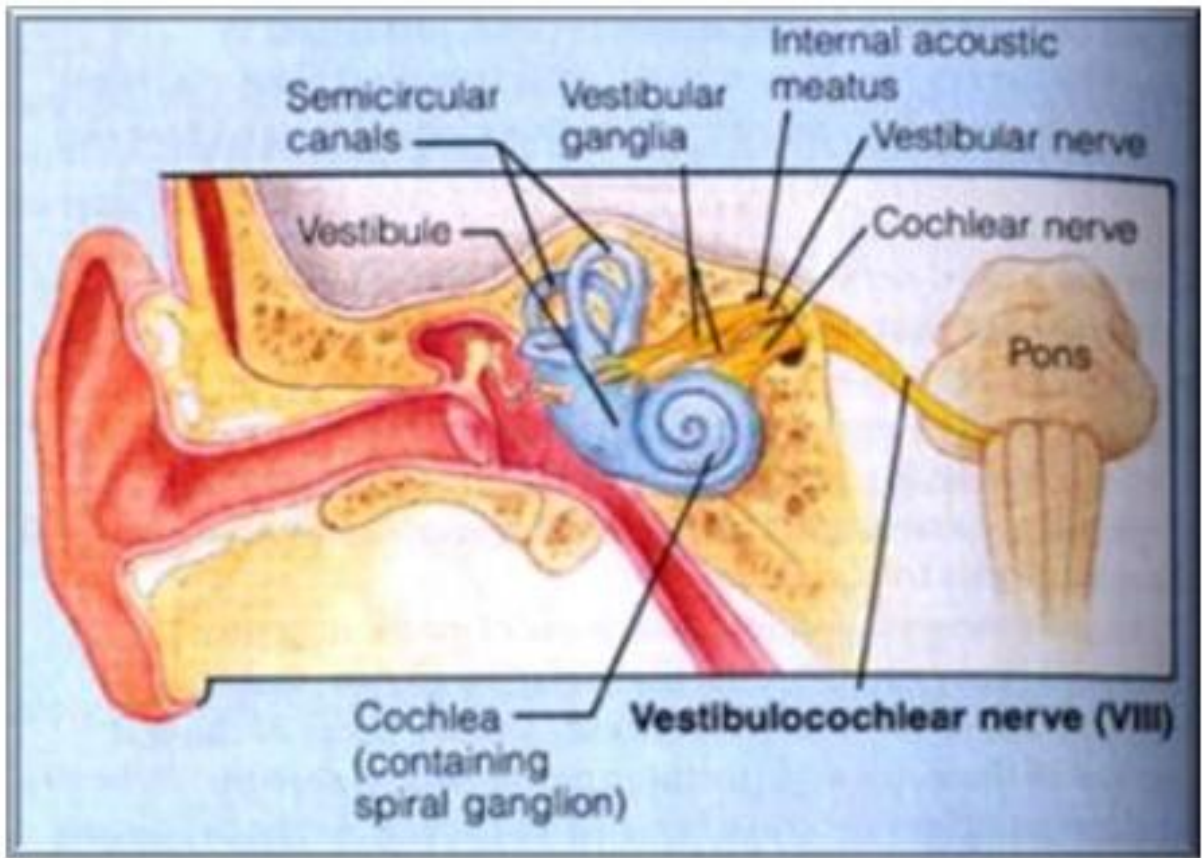
- Function:

- Vestibular – Saculae, saccule, semicircular canals – position of head
- Cochlear – Organ of Corti – hearing

- Origin: Medulla oblongata

- Opening to the Skull: Internal acoustic meatus

VIII. Vestibulocochlear Nerve



GLOSSOPHARYNGEAL NERVE

»» Cranial Nerve IX

IX. Glossopharyngeal Nerve

✓ Component: **Mixed**

✓ Function:

- **Motor**
- Stylopharyngeus muscle - assists swallowing

✓ Function:

- **Sensory**
- General sensation and taste from post. ½ of the tongue and pharynx
- Carotis sinus and carotid body

✓ Function:

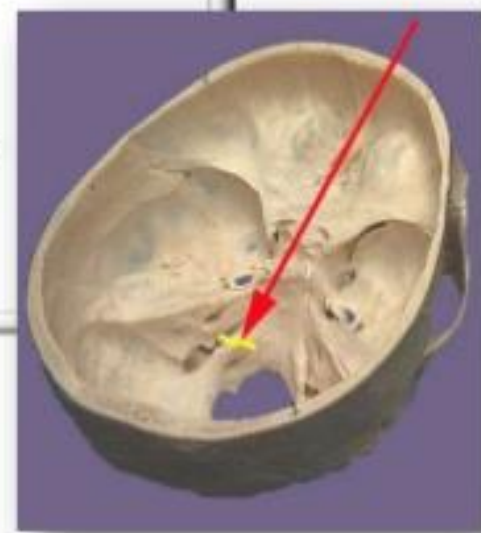
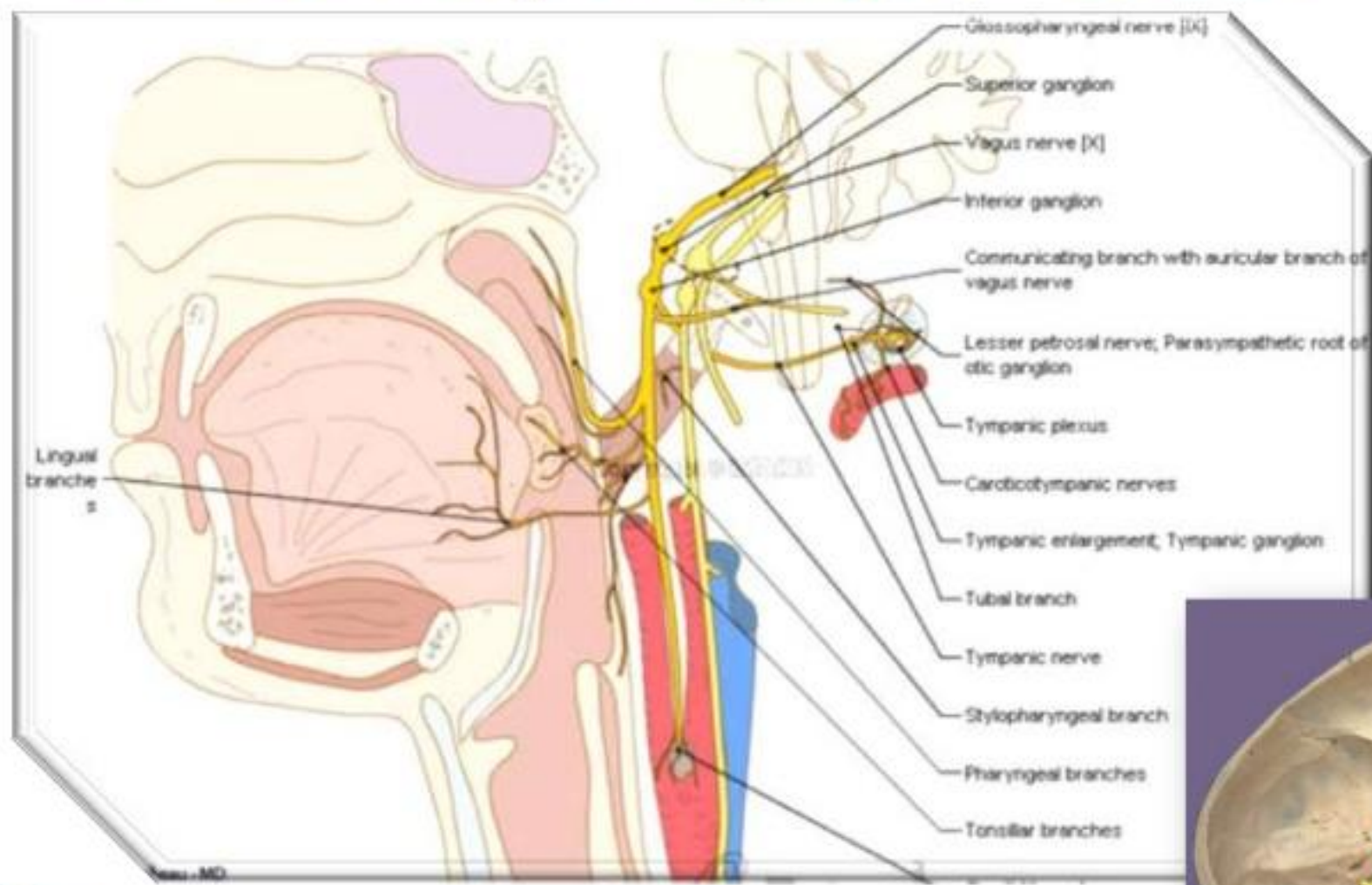
- **Secretomotor**
- Parotid gland

IX. Glossopharyngeal Nerve

✓ Origin: **Medulla oblongata**

✓ Opening to the Skull: **Jugular foramen**

IX. Glossopharyngeal Nerve



VAGUS NERVE

»» Cranial Nerve X

X. Vagus Nerve

✓ Component: **Motor**

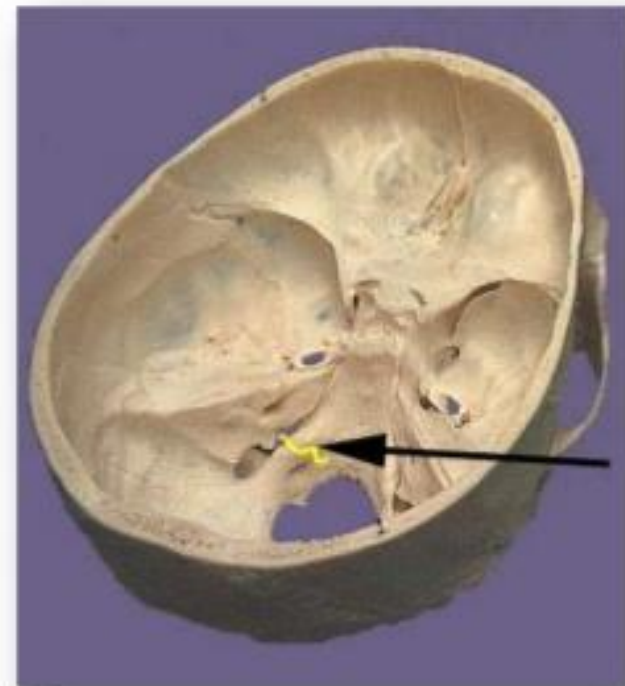
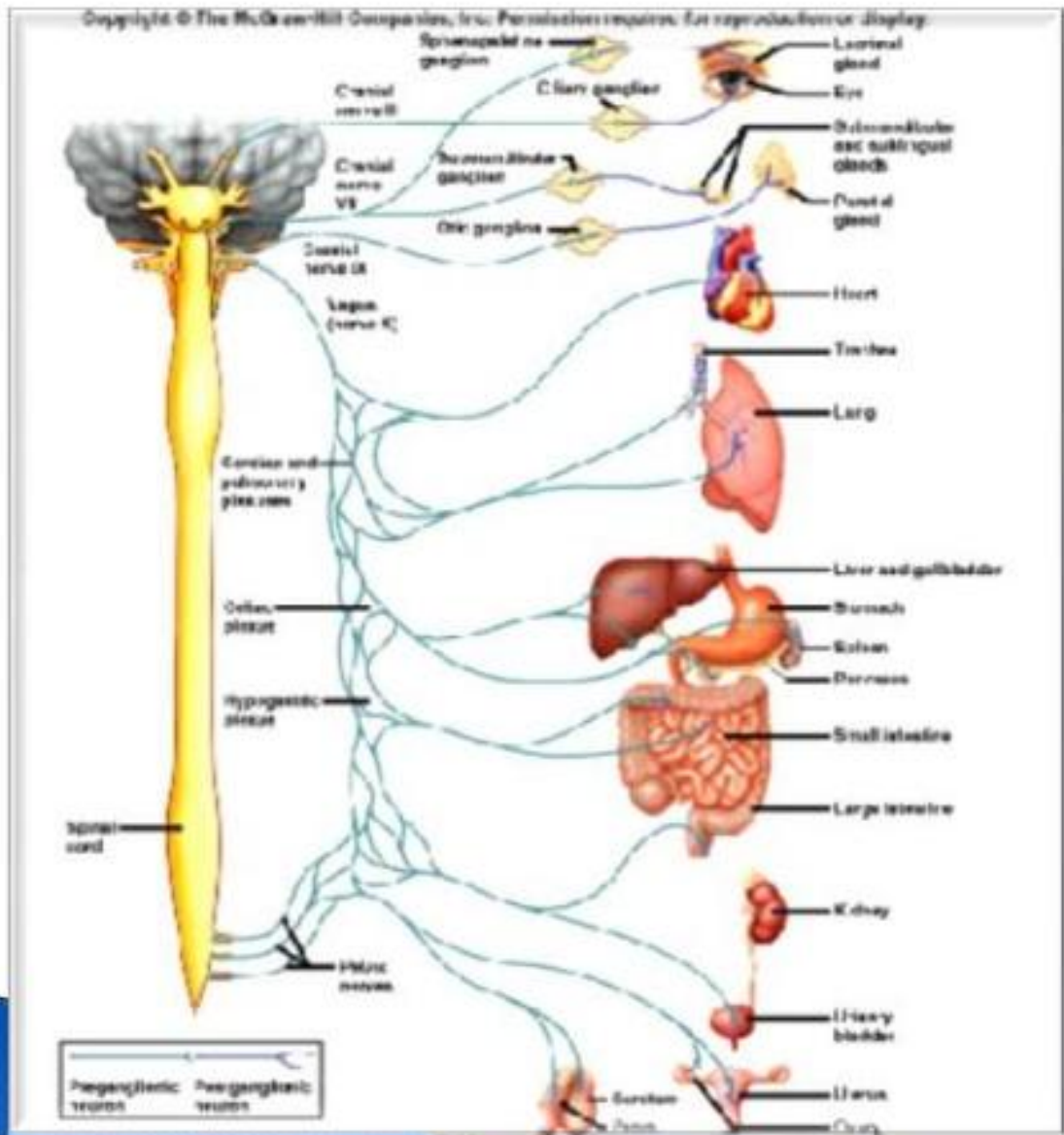
✓ Function:

- ✓ Heart and great thoracic blood vessels
- ✓ Larynx, trachea, bronchi and lungs
- ✓ Alimentary tract from pharynx to splenic flexure of colon
- ✓ Liver, kidney, pancreas

✓ Origin: **Medulla oblongata**

✓ Opening to the Skull: **Jugular foramen**

X. Vagus Nerve



ACCESSORY NERVE

»» Cranial Nerve XI

XI. Accessory Nerve

❖ Component: **Motor**

❖ Function:

❖ **Cranial root**

- ❖ Muscles of soft palate (except tensor veli palatini)
- ❖ Muscles pharynx (except styopharyngeus)
- ❖ Muscles of larynx (except cricothyroid)

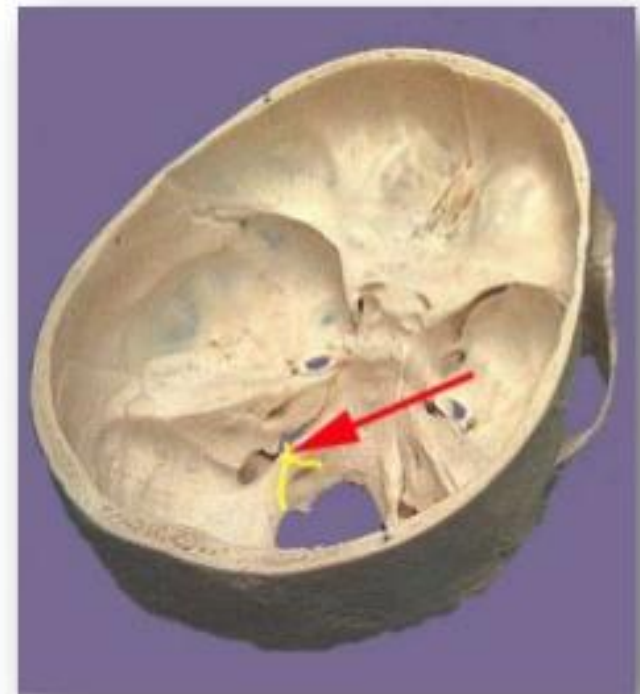
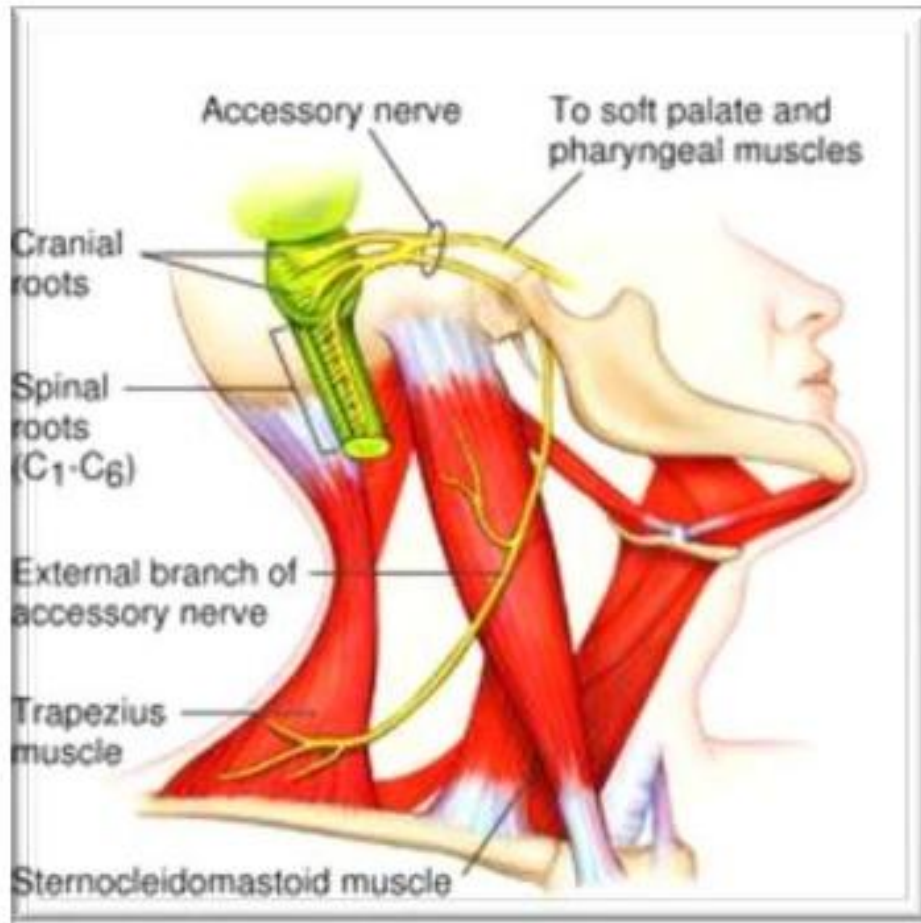
❖ **Spinal root**

- ❖ Sternocleidomastoid and trapezius muscle

❖ Origin: **medulla oblongata**

❖ Opening to the Skull: **Jugular foramen**

XI. Accessory Nerve



HYPOGLOSSAL NERVE

»» Cranial Nerve XII

XII. Hypoglossal Nerve

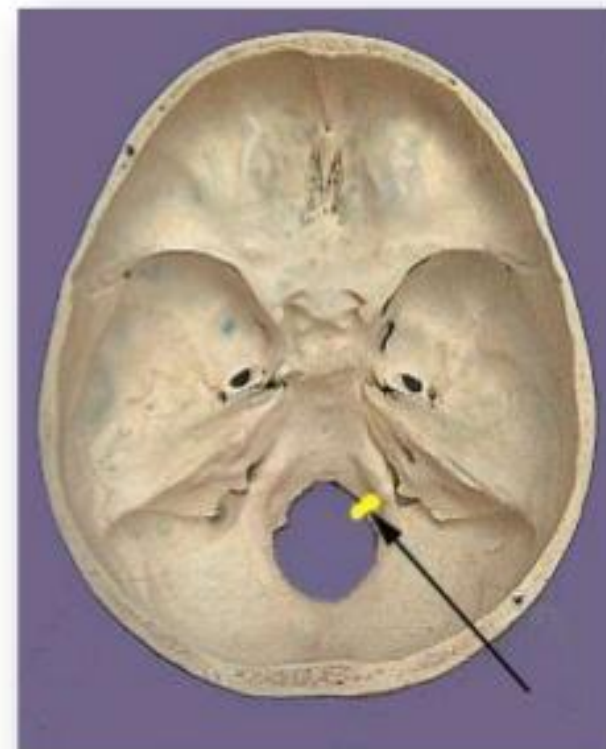
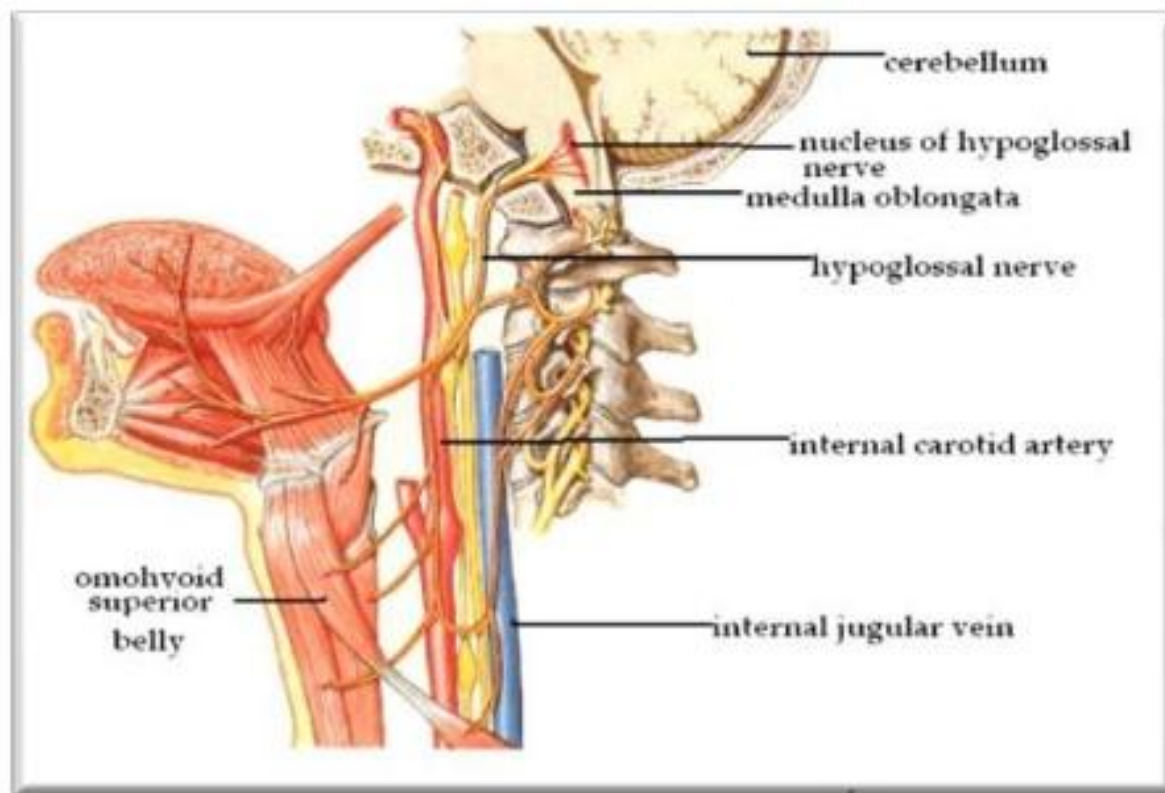
❑ Component: Motor

❑ Function: Muscles of tongue (except palatoglossus controlling its shape and movement)

❑ Origin: Medulla oblongata

❑ Opening to the Skull: Hypoglossal canal

XII. Hypoglossal Nerve



Blood Supply of the Face & Mouth

Dr. Asadullah Bisharat

BDS, BLS (The University of Lahore, Lahore) 2014

کتاب پیاویج

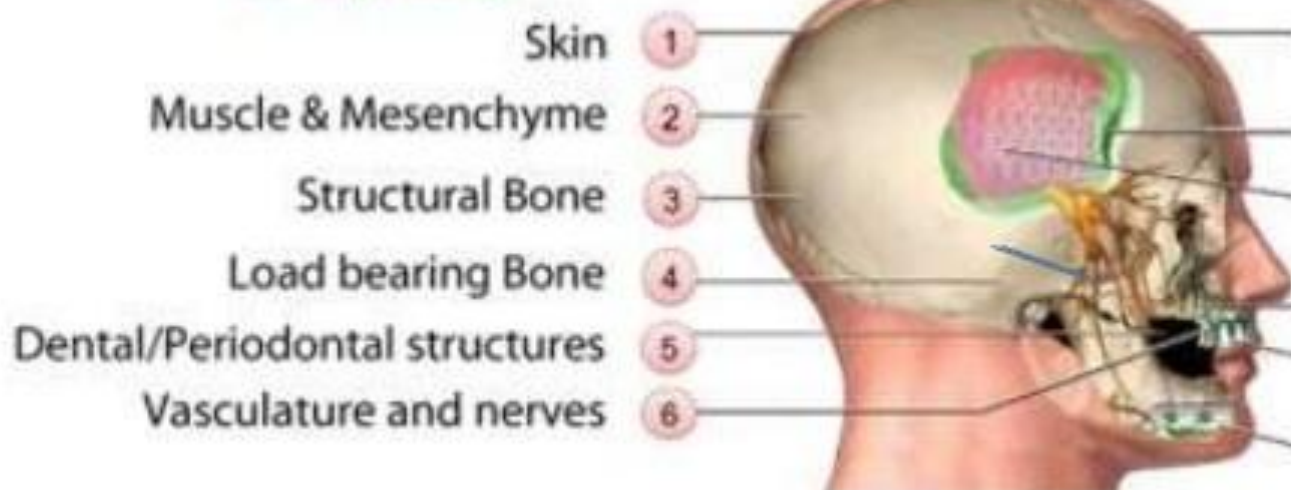

“SPECIFIC OBJECTIVES”

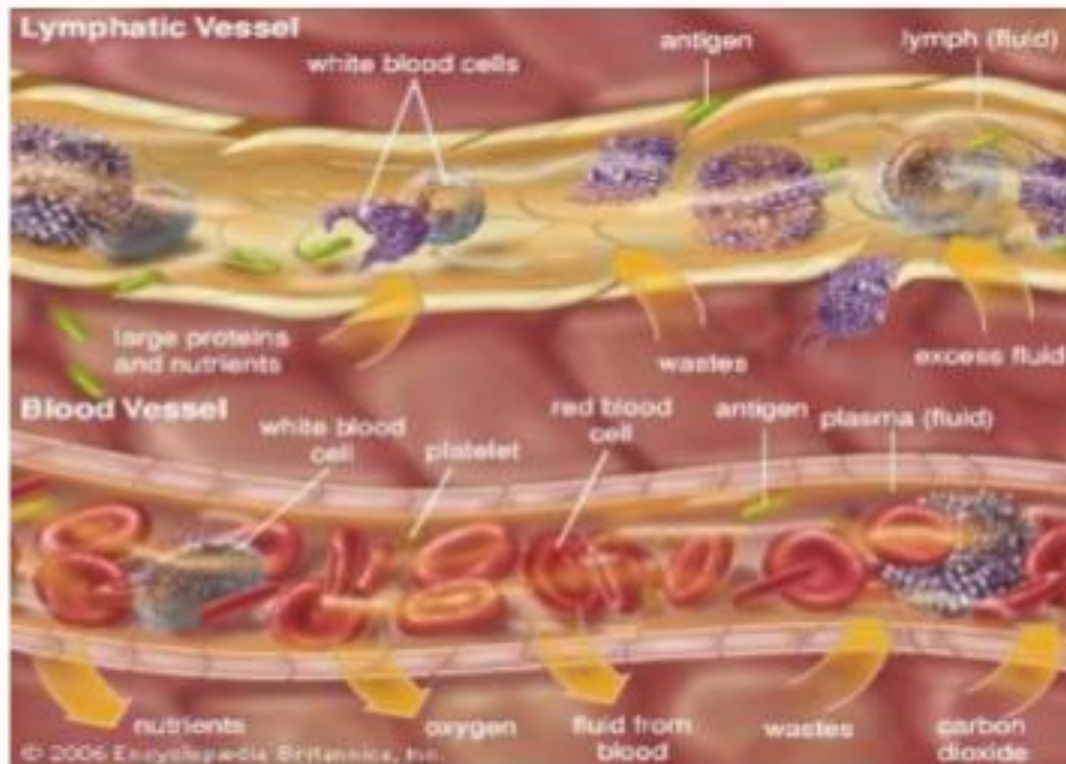
To identify the blood vessels that supplies the craniofacial complex

*The craniofacial complex comprises the bones and soft tissues of the cranium, face, and oral cavity and is the most distinguishing of all the structures in the human body, imparting unique identities to individuals.

Craniofacial Complexity



*The lymphatic vessels are structures of the lymphatic system that collect, filter, and transport lymph fluid away from tissues.



*The blood vessels are part of the circulatory system that transports blood throughout the human body.

“Blood Vessels That Supplies The Craniofacial Complex”

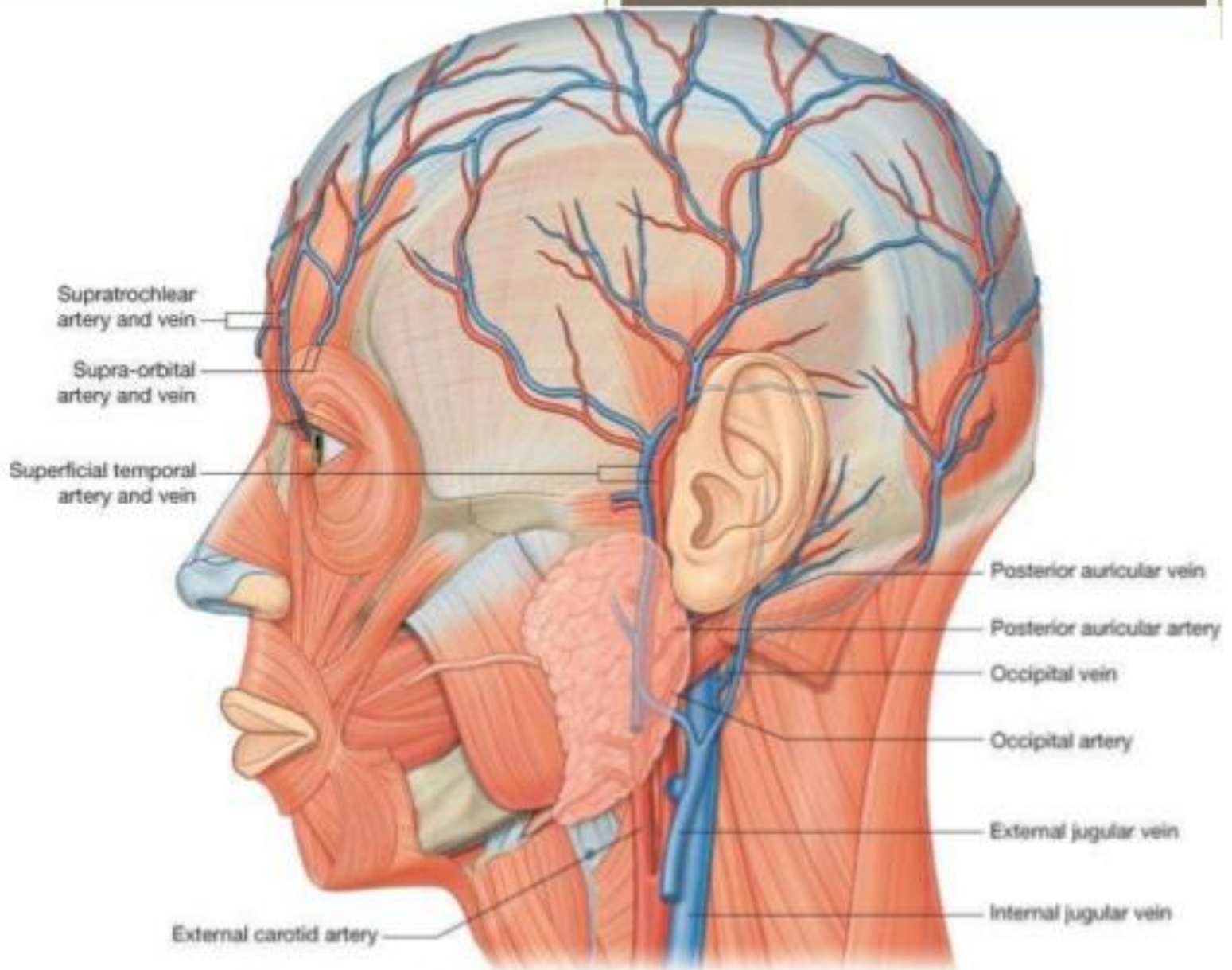
- The *external carotid* arteries supply oxygenated blood to the head, face, mouth and neck.

***Occipital artery:** supplies blood to the back of the scalp and sternomastoid muscles. Other muscles it supplies are deep muscles in the back and neck.

***Posterior auricular artery:** supplies blood to the scalp posterior to the auricle and to the auricle itself.

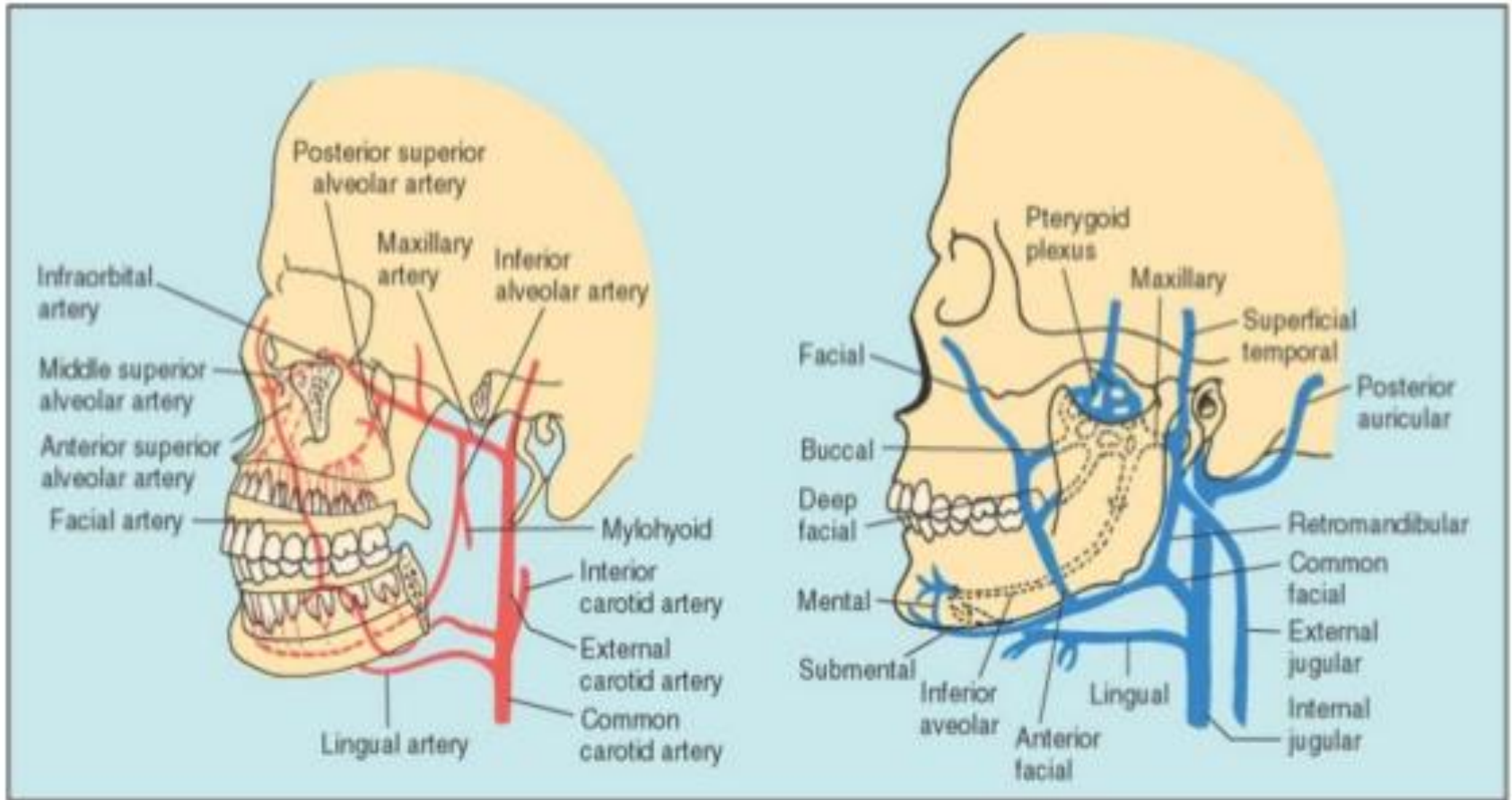
***Superior labial branches of the facial arteries and infraorbital arteries:** Supply blood to the upper lip.

***Inferior branches of the facial arteries and mental arteries:** Supply the lower lip.



Drake: Gray's Anatomy for Students, 2nd Edition.

Copyright © 2009 by Churchill Livingstone, an imprint of Elsevier, Inc. All rights reserved.



RED: Artery

BLUE: Vein

***Superior alveolar arteries** (from the maxillary artery): Supply blood to the upper teeth.

***Inferior alveolar arteries** (from the maxillary artery): Supply the lower teeth.

***Greater and lesser palatine arteries**: Supply the palate.

***Branches of the lingual artery**: Supply blood to the tongue

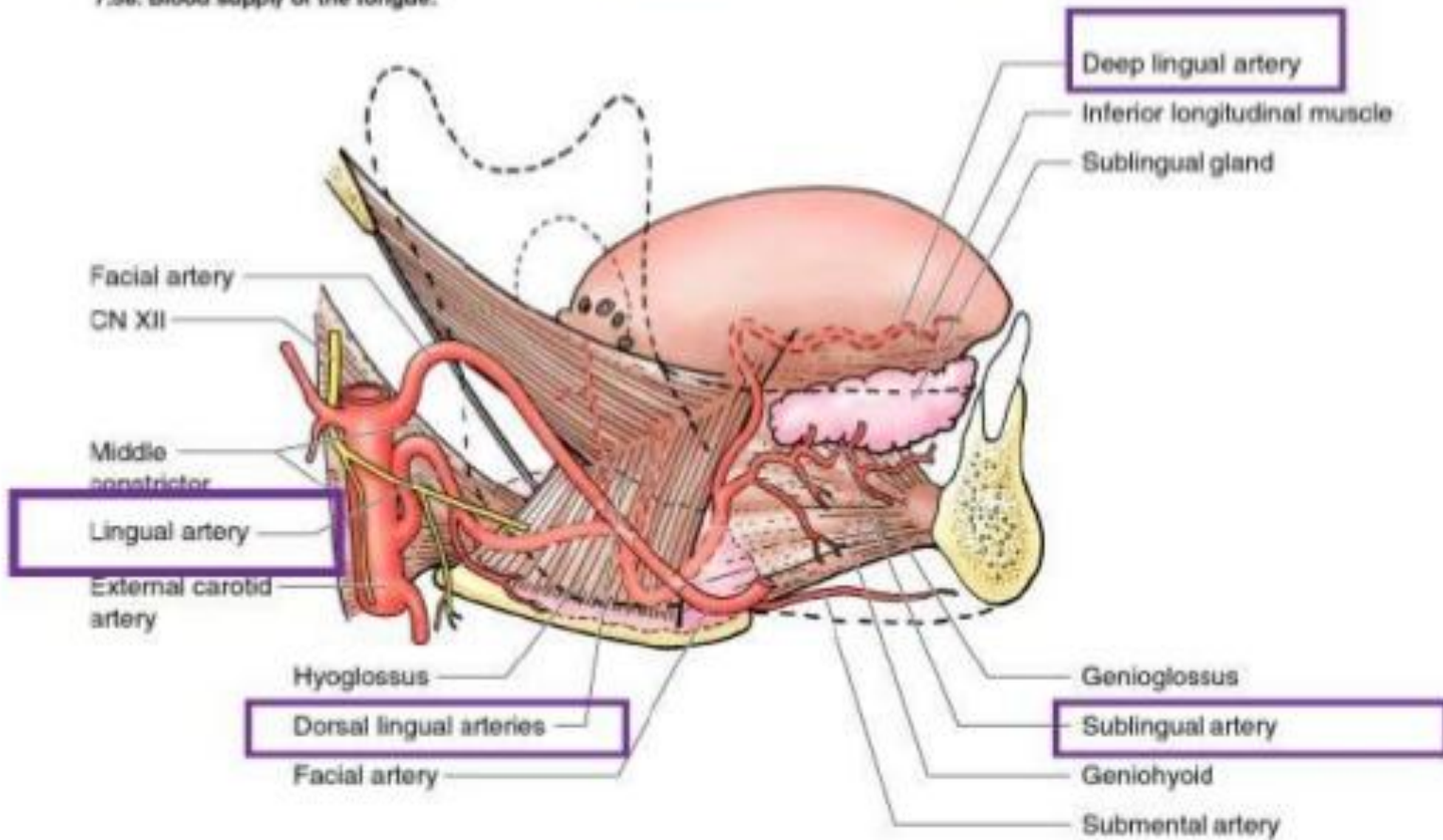
>Dorsal lingual arteries: Supply the posterior part of the tongue.

>Deep lingual artery: Supplies the anterior part of the tongue and communicates with the dorsal arteries at the apex.

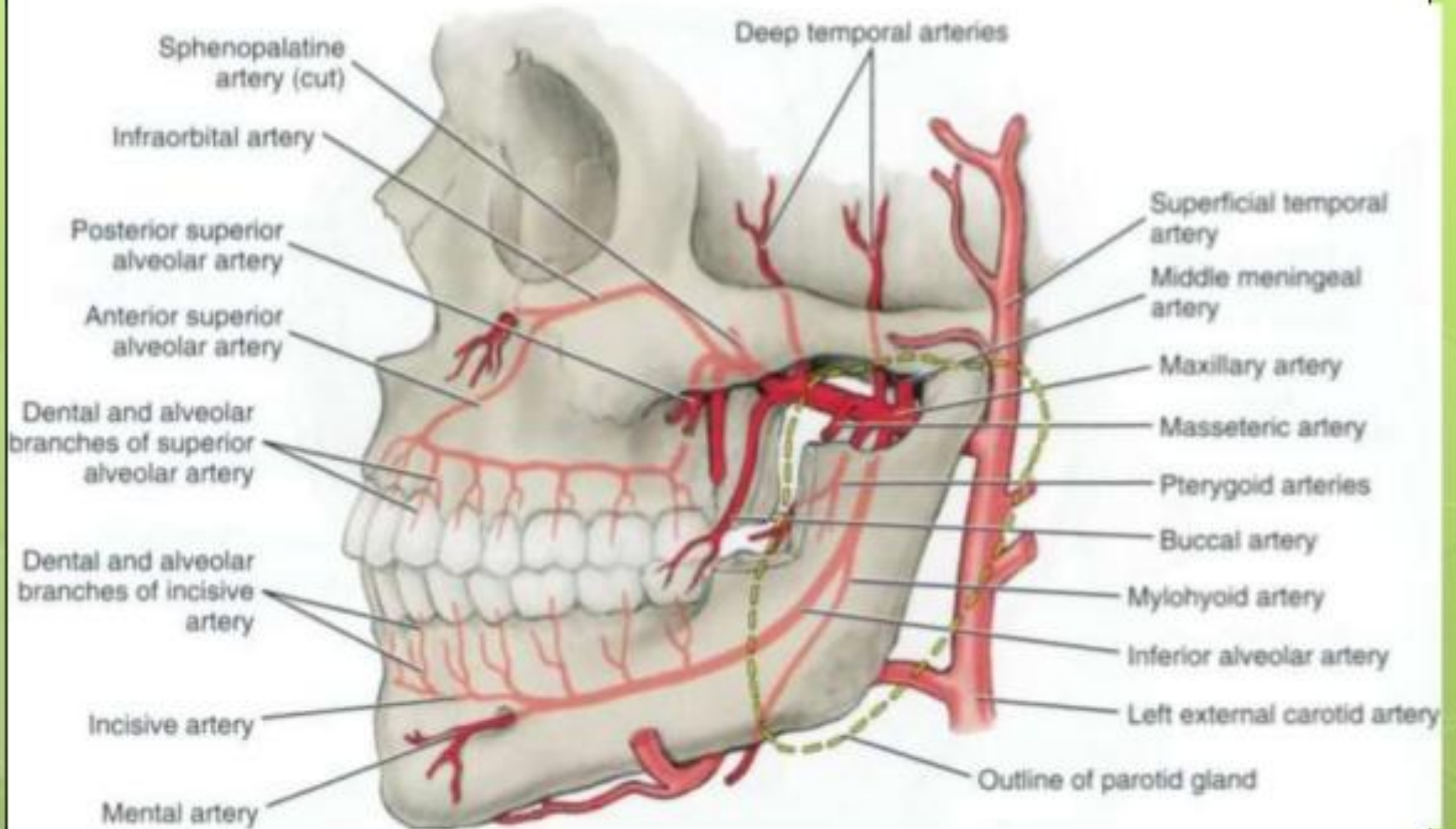
>Sublingual artery: Supplies the sublingual gland and the floor of the oral cavity.

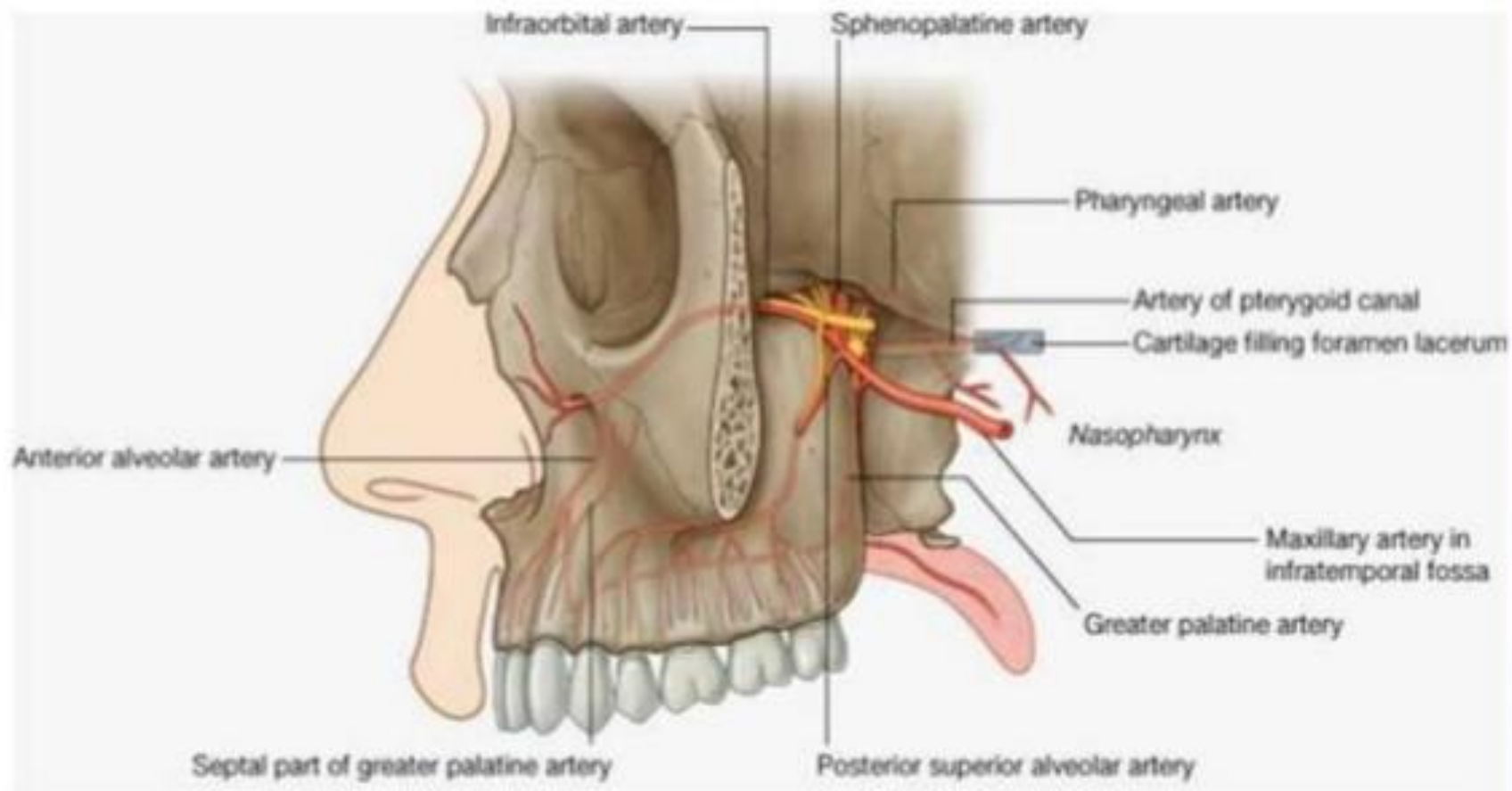
Arterial Supply to the Tongue

7.58. Blood supply of the tongue.



- ***Branches of the external carotid and superficial temporal arteries:** Supply the parotid salivary glands.
- ***Submental arteries:** Supply the submandibular glands and sublingual glands.
- ***Anterior and posterior deep temporal, pterygoid, masseteric, and buccal arteries:** Which supply chiefly the muscles of mastication.
- ***Pharyngeal artery:** Supplies the roof of the nose and pharynx, sphenoid sinus, and auditory tube.
- ***Sphenopalatine artery:** Is the principal artery to the nasal cavity, supplying the conchae, meatus, and paranasal sinuses.





- The *internal carotid* artery supplies the brain, the eye and its appendages, and sends branches to the forehead and nose.

***Ophthalmic artery:** Is a branch of the internal carotid artery that supplies the structures within and around the eye orbit.

>Central artery of the retina: Is the most important branch of the ophthalmic artery which does not connect with any other arteries.

>Supraorbital and Supratrochlear artery: Supplies the forehead and the scalp.

>Dorsal nasal artery: Supplies the side of the nose and the lacrimal sac.

>Long posterior ciliary arteries: Supply the ciliary body and the iris.

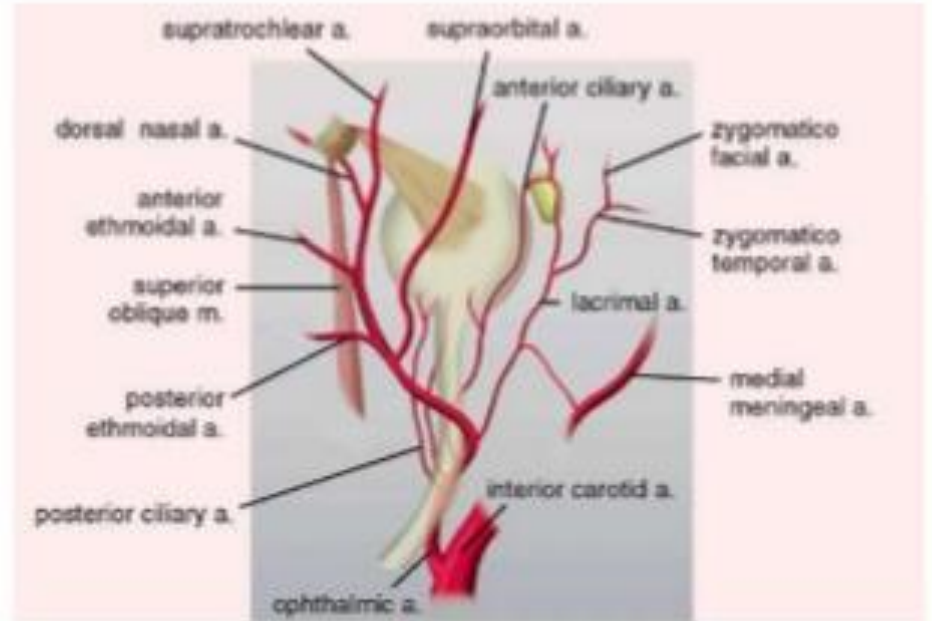
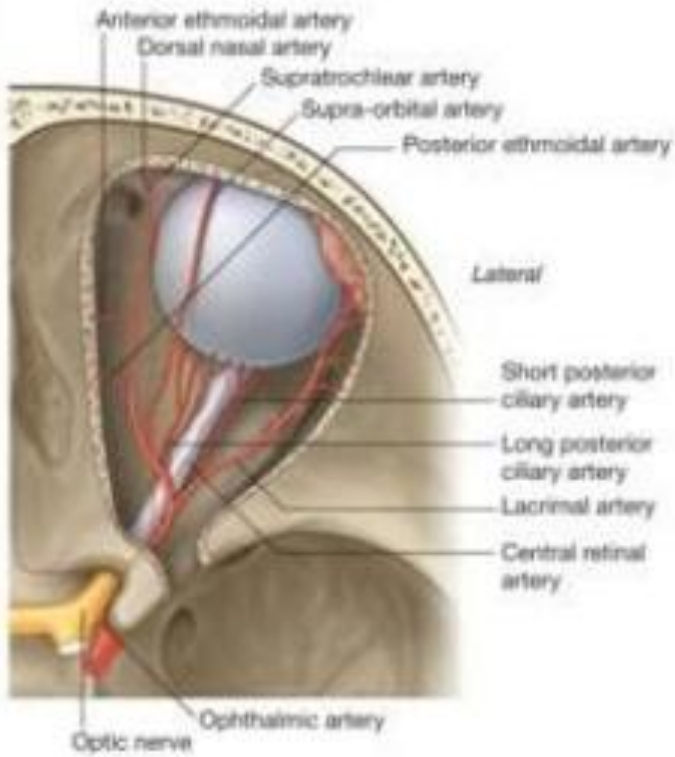
>Short posterior ciliary arteries: Supply the choroid.

>Lacrimal artery: Supplies the lacrimal gland, conjunctiva, and eyelids.

(Note: Veins of the oral cavity generally follow the arteries and have the same names.)

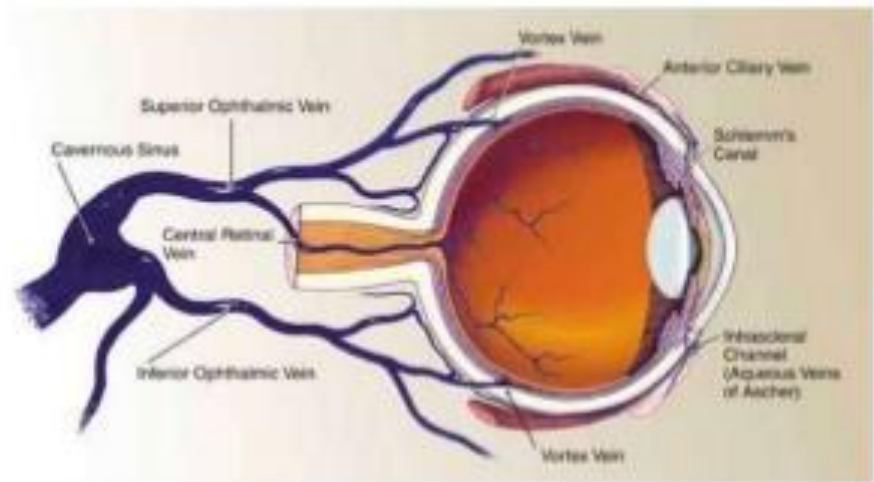
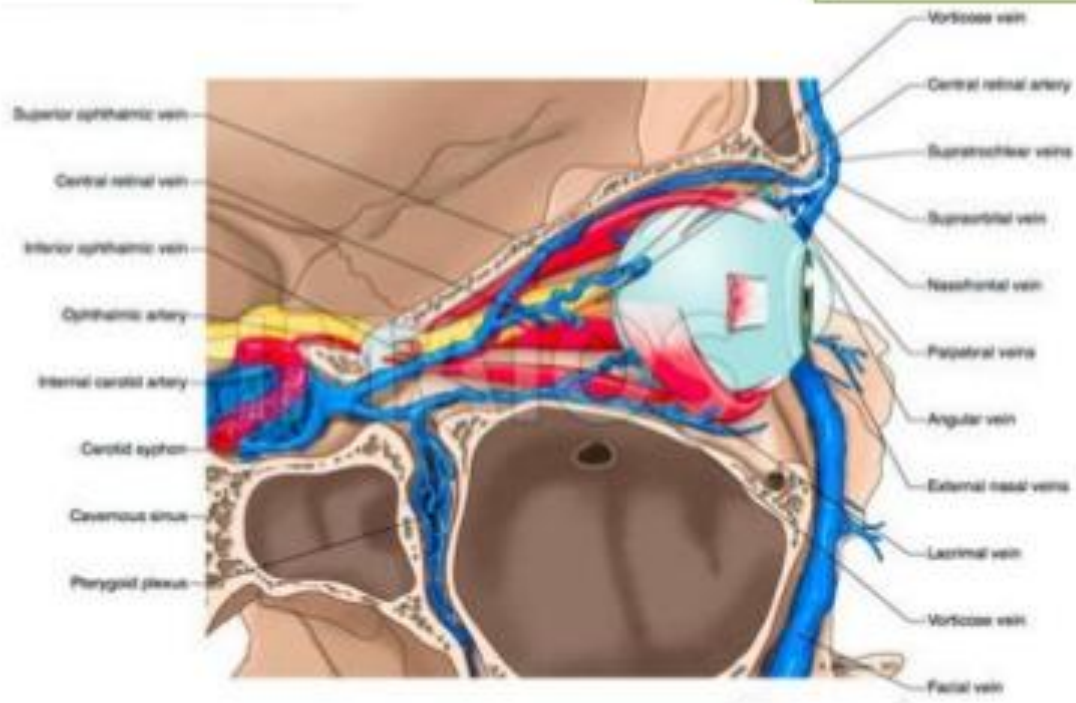
***Internal jugular vein:** Collects blood from the brain, the outside of the face and the neck.

***External jugular vein:** Collects most of the blood from the outside of the skull and the deep parts of the face.



“VENOUS DRAINAGE OF THE CRANIOFACIAL COMPLEX”

- ***Ophthalmic vein:** Is where the orbital cavity drains. (Superior and Inferior ophthalmic vein)
- ***Retromandibular vein:** Is formed by the superficial temporal vein and the maxillary vein. Drain the face.
- ***Posterior Auricular vein:** drains the area of the scalp superior and posterior to the outer ear.
- ***Internal Jugular vein:** Drain blood from the anterior of the face.



ANATOMY OF THE ORAL CAVITY

Dr. Asadullah Bisharat

BDS, BLS (The University of Lahore, Lahore) 2014

کتاب پیاویج

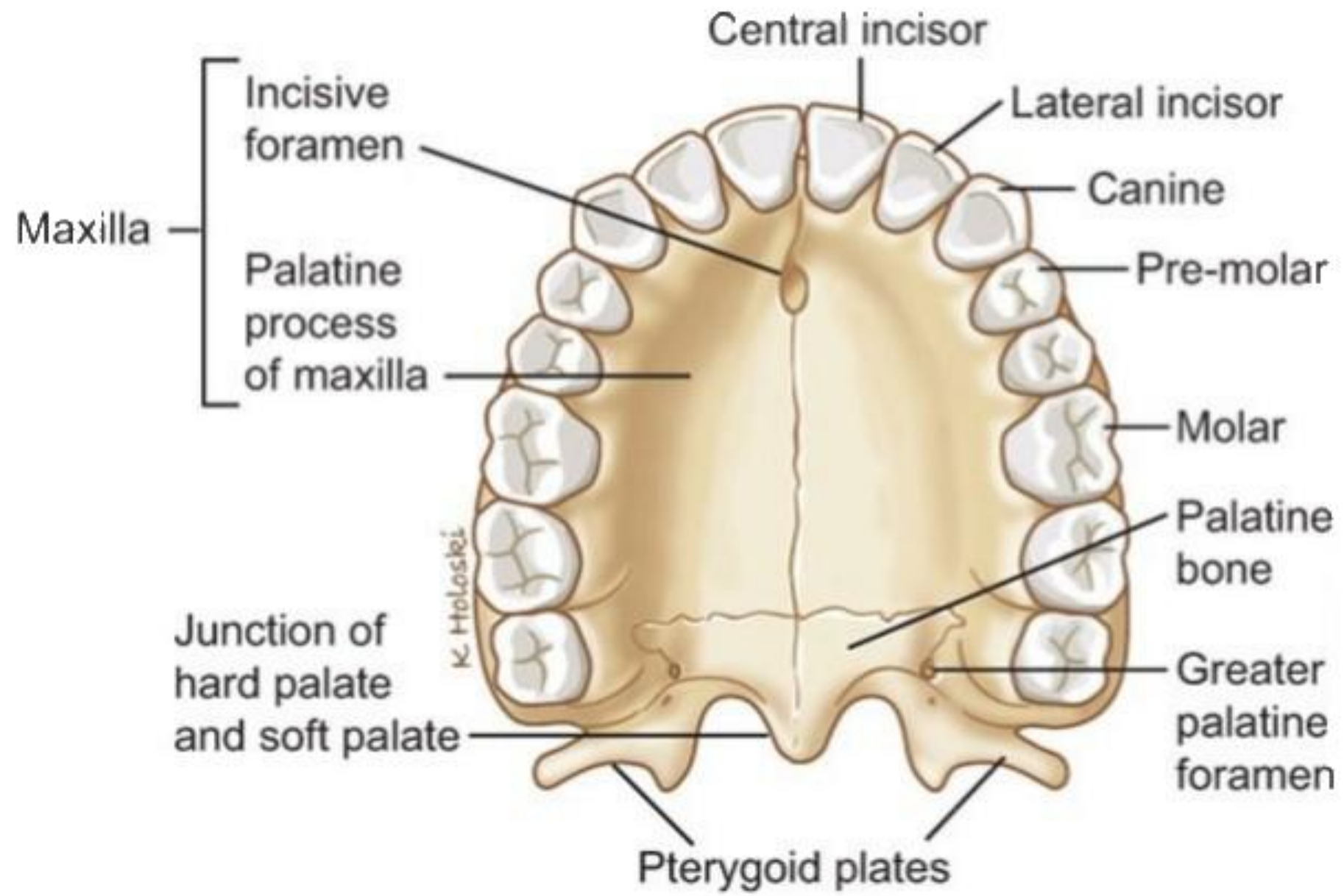
gap

Lectuer out line:

- 1. The palate.**
- 2. The tounge.**
- 3. Floor of the mouth.**
- 4.Salivery gland in the floor of the mouth.**
- 5. Parotid gland.**
- 6. Tempromandibular joint.**

Palate

- The skeleton of the hard palate provided by the palatine processes of the maxilla and the horizontal processes of the palatine bones.
- Its oral surface is covered by mucous membrane lined by stratified squamous epithelium divided in to two parts
- Anteriorly is the ***hard palate*** which forms the partition between the nasal and the oral cavities.
- Posteriorly ***soft palate*** which attached to the posterior border of the hard palate and projects posteriorly in to the pharynx, separating its oral and nasal parts.(Its highly mobile and its movement important in preventing food and drink entering the nasopharynx and nose during the act of swallowing).



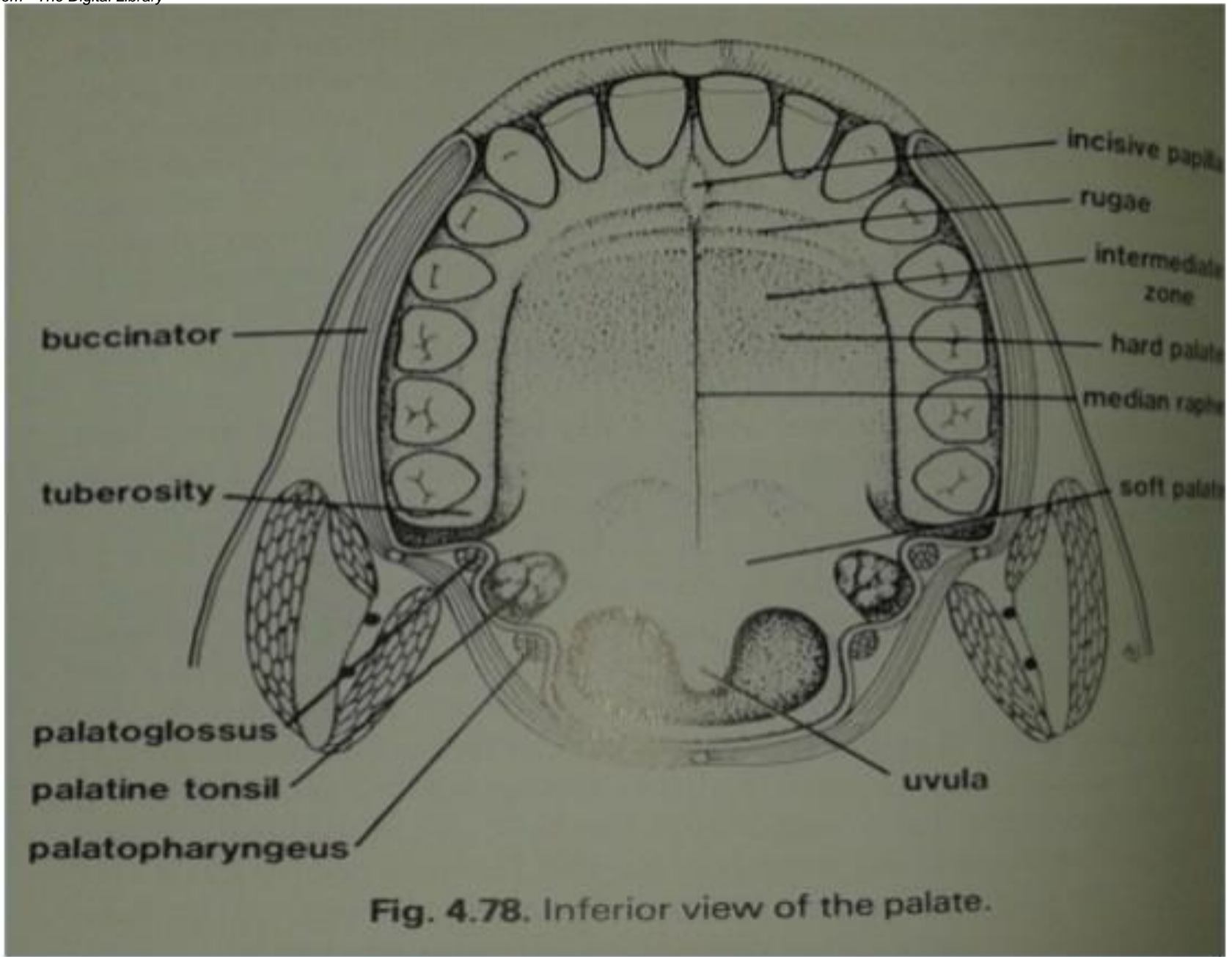


Fig. 4.78. Inferior view of the palate.

- The submucous layer varies in thickness from one region to another and absent in some area.
- This variation in the submucous layer produces 3 zone:
- In the ***gingival region*** and ***palatine raphe*** absent submucous layer the mucosa is pink and tightly adherent to the bone
- Between the raphe and the gingival region on each side is an ***intermediate zone*** in which the submucosa is relatively well developed
- Anterior to the intermediate zone the space between the lamina propria and the periosteum fill with adipose tissue and the mucous membrane is thick and pale

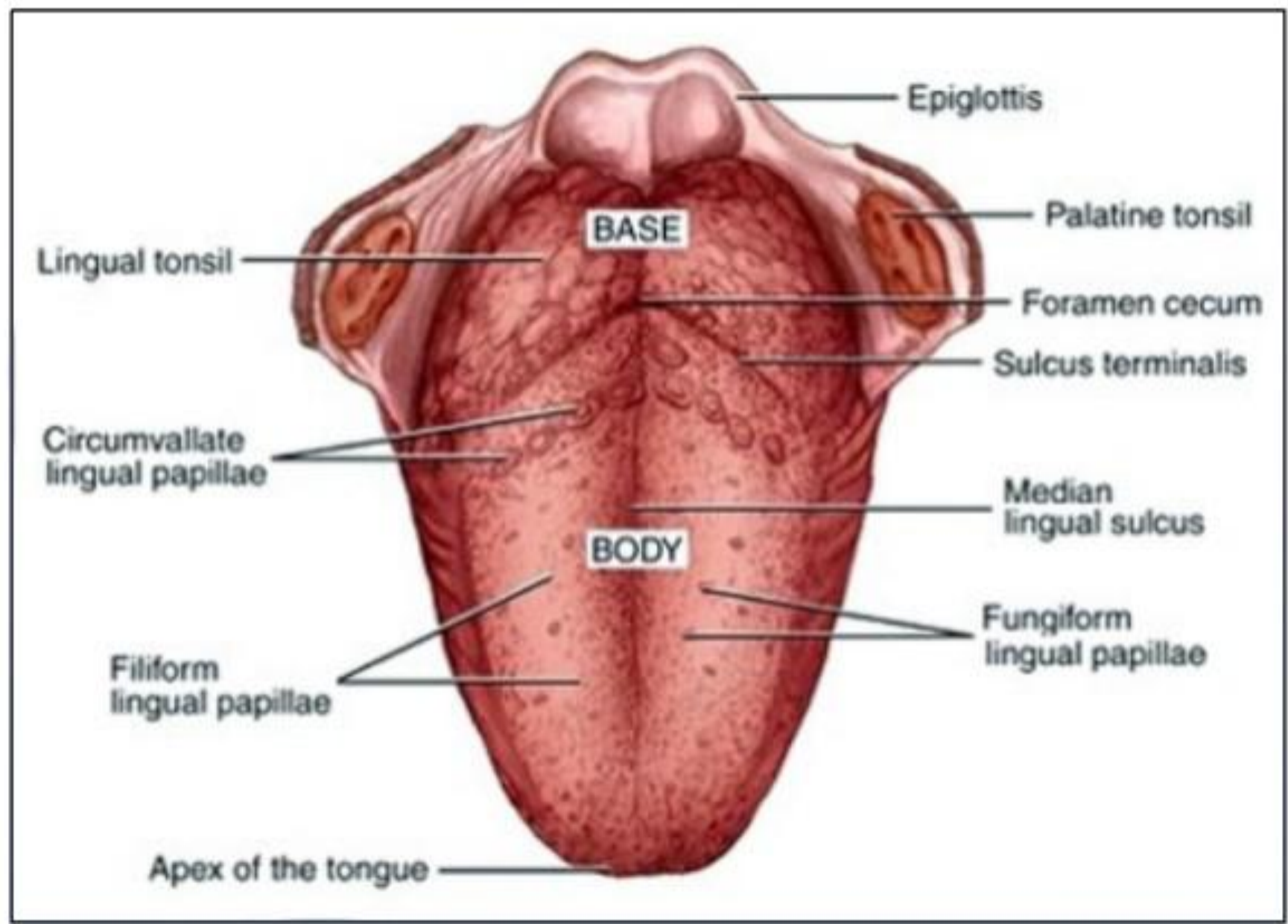
And present of trasverse corrugation called ***palatine rugae***.

- The palatine raphe ends anteriorely at small elevation, the incisive papilla, overlying the ***incisive fossa*** (nasopalatine nerve emergs in to the hard palate through this fossa)
- Behind the last molar tooth the alveolar process ends in arounded prominences, the ***maxillary tuberosity***
- The ***greater palatine foramen*** carryy the greater palatine artery and nerve.
- The ***lesser palatine foramen*** carryy the lesser palatine artery and nerve.

The Tongue

- The tongue is highly mobile , muscular organ which play amajor part in the mechanisms of swallowing and speech. Covered by mucous membrane.
- The dorsum of the tounge is divided by the V_ shaped sulcus terminalis in to anterior two third and posterior one third (differ in epithelial specalisation, development, and nerve supply).
- The apex of the sulcus terminalis is marked by shallow median pit (foramen caecum) marking the embrryological origion of the thyroid gland and the upper end of the transient thyroglossal duct.
- The anterior 2/3 covered by mucous membrane tightly bound to the underlying muscle and bearing stratified squamous epithelium formed in to neumerous papillae

- ***Filiform papillae***: most numerous 2_3 mm long arranged in rows parallel to the arms of the sulcus terminalis.
- ***Fungiform papillae***: less numerous slightly constricted stalk and a hemispherical upper part, appears on the tongue as bright red spot due to rich blood supply (side, tip).
- ***Vallate papillae***: 12 in number largest and situated parallel and immediately anterior to the sulcus terminalis recessed in the mucous membrane and surrounded by a deep circular furrow serous gland of (Von Ebner) open into the bottom of the furrow and help to rinse the area around the papillae.
- ***Foliate papillae***: appear on the posterior part of the lateral margins of the tongue as several vertical folds this fold are rudimentary in man but its well developed in other mammals.



- **filiform and fungiform papillae are absent in the posterior 1/3 of the tongue but the mucous membrane is raised in to neumerous low elevation by the presence of nodules of lymphoid tissue in the submucous layer known as (lingual tonsil)**
- **Surface of each papilla bears alarge number of taste buds.**
- **The taste buds distenguish only four sensation sweet and salt (tip of the tongue) , bitter (posterior part of the tongue), acid (both side of the tongue). Taste buds are found on the palatoglossal arches, the soft palate, the posterior surface of the epiglottis and the postreior wall of the pharynx as far down as the inferior margion of the cricoid cartilage.**

- ***Ventral surface of the tongue*** : Area under the tongue smooth and covered by a thin mucous membrane, the median fold called the ***Lingual frenulum*** connects the inferior surface of the tongue to the floor of the mouth.
- On each side of the frenulum is a fringed fold of mucous membrane called ***Plica fimbriata***.
- Between the frenulum and the plica, the deep lingual vein.
- Short lingual frenulum leads to "***tongue tie***".
- Associated with the mucous membrane are numerous lingual glands; over the posterior one-third they are mainly mucus-secreting and over the anterior two-thirds serous glands are found and few mucous glands are present near the tip of the tongue.

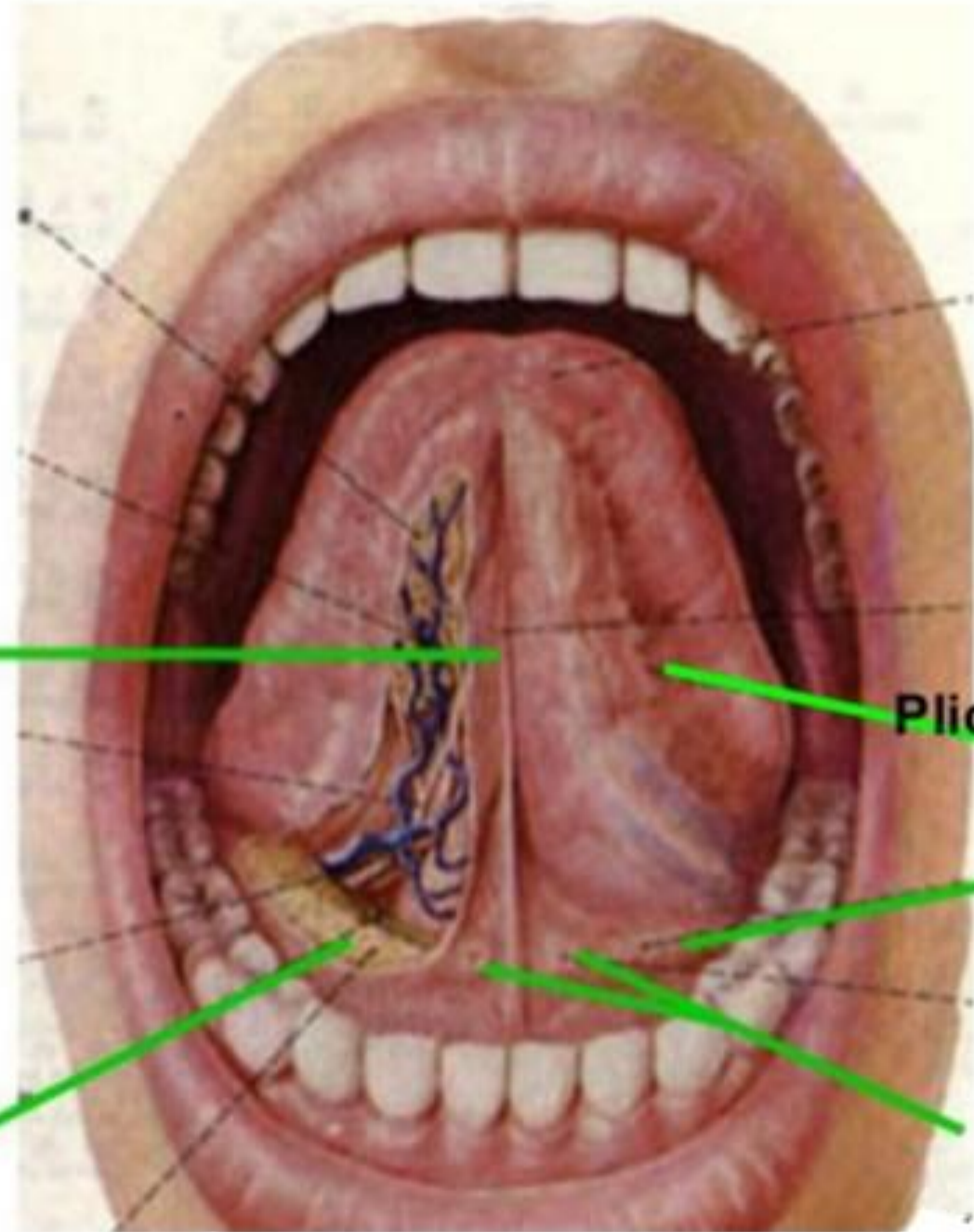
frenulum of tongue

Plica fimbriata

sublingual fold

sublingual gland

sublingual caruncle



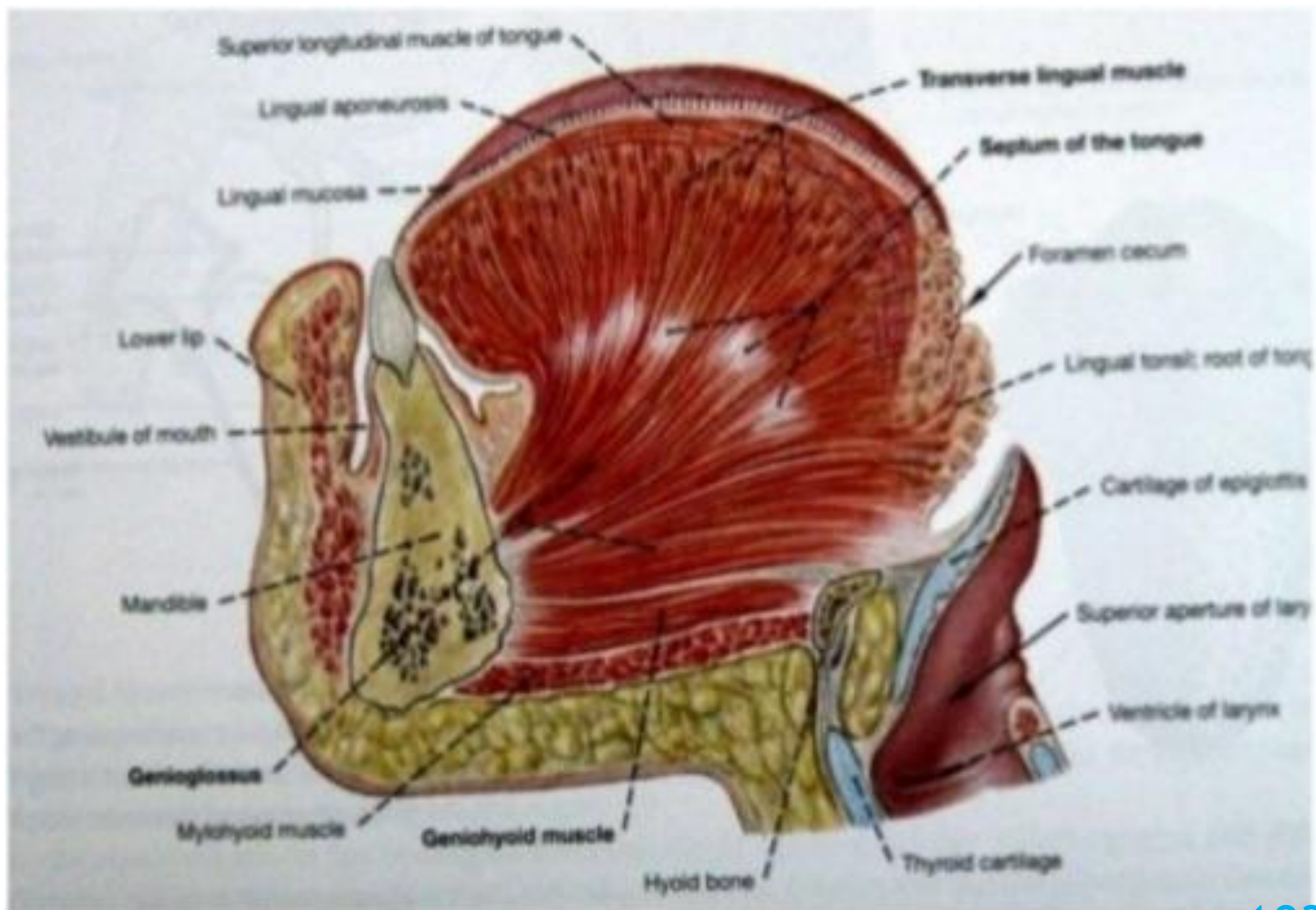
- **Bulk of the Tongue made up of striated muscle divided in to two components: Internsic and extrinsic muscles.**
- **All the extrinsic muscle inervated by hypoglossual nerve except palatoglossus which inervated by pharngeal plexus of the accessory nerve.**
- **All of the intinsic muscle are inervated by hypoglossual nerve.**
- **Blood supply: lingual artery.**
- **Venous drainage :ls via the lingual and deep lingual veins.**

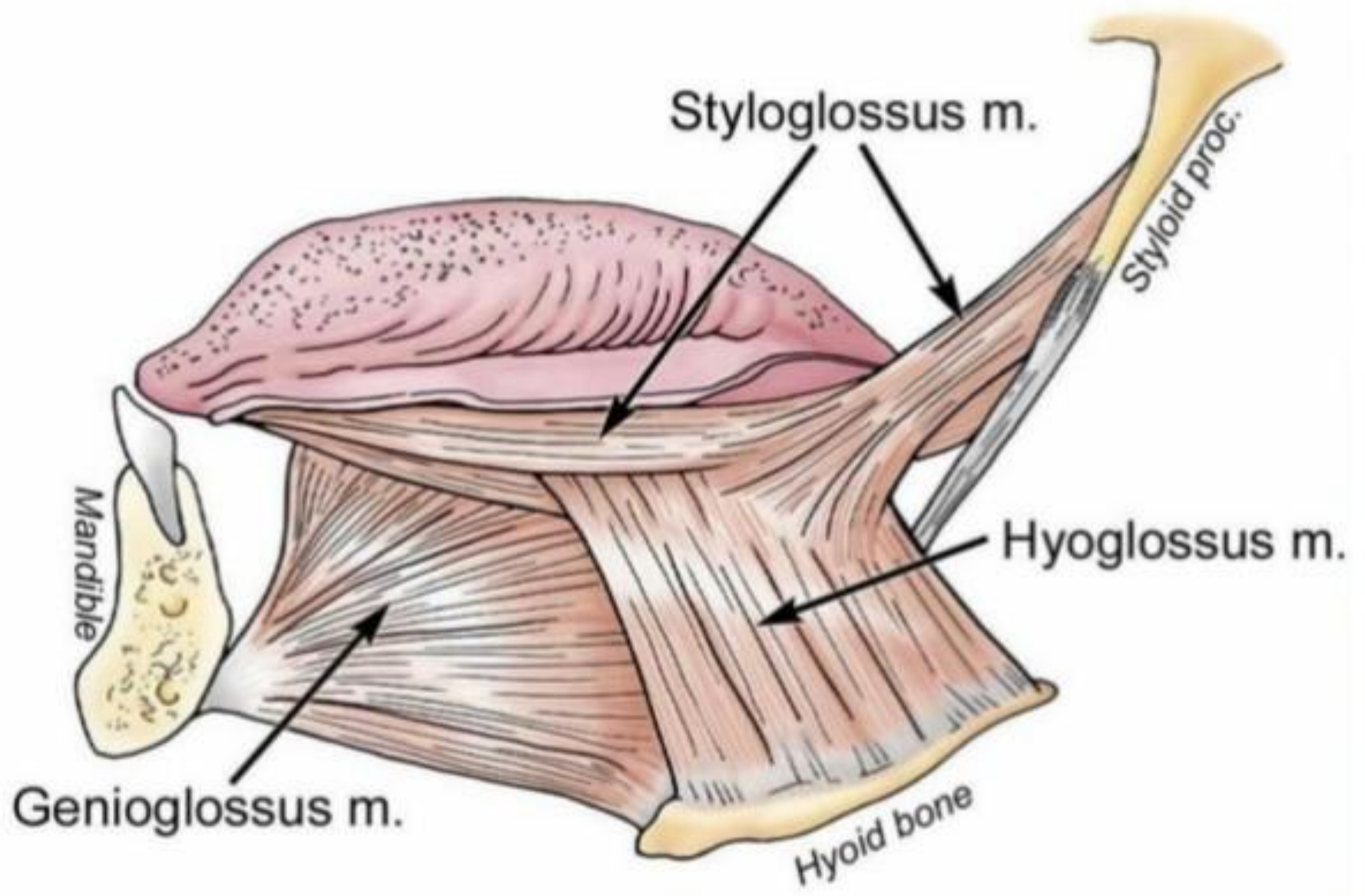
Intrinsic muscles

muscle	Origion and insertion	Action
Transverse muscle	From the median septum and pass lateraly to be inserted into the side of the tongue.	Narrow and elongate the tongue.
Superior Longitiudinal muscle	Attached to the mucus membrane over the posterior part of the tongue and run forward to attaches to the mucus membrane at its edges and tip.	Shorting the tongue and turn its tip and edges upwards.
Inferior longitudinal fibers	Situating lateral to genioglossus in the lower part of the tongue.	Shorten the tongue turn its tip and edges downwards.
Vertical fibers	Run from the dorsum of the tongue to the mucus membrane on its ventral surface.	Flatten and broaden the tongue.

Extrinsic muscles

muscle	Origion and insertion	Action
Genioglossus	From the upper mental spine of the mandible, its fiber run posteriorly upward and downward.	Aprotracture and depressor.
Hyoglossus	From the superior border of the greater horn of the hyoid bone and passes vertically upward.	Depress the tongue.
Styloglossus	From the anterior surface of the styloid processes run forward downward to enter the tongue below the insertion of the palatoglossus muscle.	Retractor of the tongue.
palatoglossus	From the aponeurosis of the soft palate and descends to the tongue.	Raise the tongue to narrow the oropharyngeal isthmus.
Condroglossus	From the lesser cornu of the hyoid and ascending to blend with the intrinsic lingual muscle.	





Lymphatic drainage: is complex because of the tendency for malignant lingual neoplasm too spread through this route. Carcinoma of the tongue may first be detected by the presence of metastases in the draining lymph node.

Plexus of lymphatic vessels in the mucus membrane and another in the musculature of the tongue. The two are continuous.

Drainage from the tongue anterior to the vallate papilla is into ***marginal and central vessels***, That from behind the papillae is into the ***dorsal vessels***.

Tip of the tongue drain into the marginal vessel descend to drain mostly into the submental node then to the jugulo-omohyoid node.

Some of the marginal vessels drain into submandibular node then to the deep cervical node.

The central vessels receive lymph from the remainder of the tongue anterior to the vallate papilla drain to jugulo-omohyoid and jugulodigastric node while others pierse mylohyoid to enter the submandibular nodes.

The dorsal vessels drain bilaterally into the jugulodigastric nodes and to jugulo-omohyoid nodes.

Floor of the mouth

- Is the region located between the medial surface of the mandible and the inferior surface of the tongue and mylohyoid muscle.
- The two mylohyoid muscles form a muscular diaphragm for the floor of the mouth. Above this diaphragm are found the genioglossus muscle, geniohyoid muscle medially and hyoglossus muscle laterally. The digastric muscle and stylohyoid muscle lie below the mylohyoid.

Mylohyoid muscle : Arise from the whole length of the mylohyoid line on the inner surface of the body of the mandible, its fiber slope downwards forwards and in wards.

- The anterior fibers interdigitate with the corresponding fibers on the opposite side to form the median raphe attached anteriorly to the chin and posteriorly to the body of the hyoid bone medially and has a free edge laterally.
- ***Action:*** Raises the floor of the mouth during the early stages of swallowing and depress the mandible when the hyoid bone is fixed.
- ***Innervation:*** By mylohyoid branch → inferior alveolar → mandibular division of the trigeminal nerve.
- ***Blood supply:*** lingual, maxillary and facial artery.

Geniohyoid muscle: Originate from the inferior genial spine passes backwards and slightly downwards to insert into the anterior surface of the hyoid bone.

- ***Action:*** elevates and draw forwards the hyoid bone and depress the mandible.

- ***Innervation:*** From the first cervical spinal nerve travelling with the hypoglossal nerve.

- ***Blood supply:*** Lingual artery (sublingual branches).

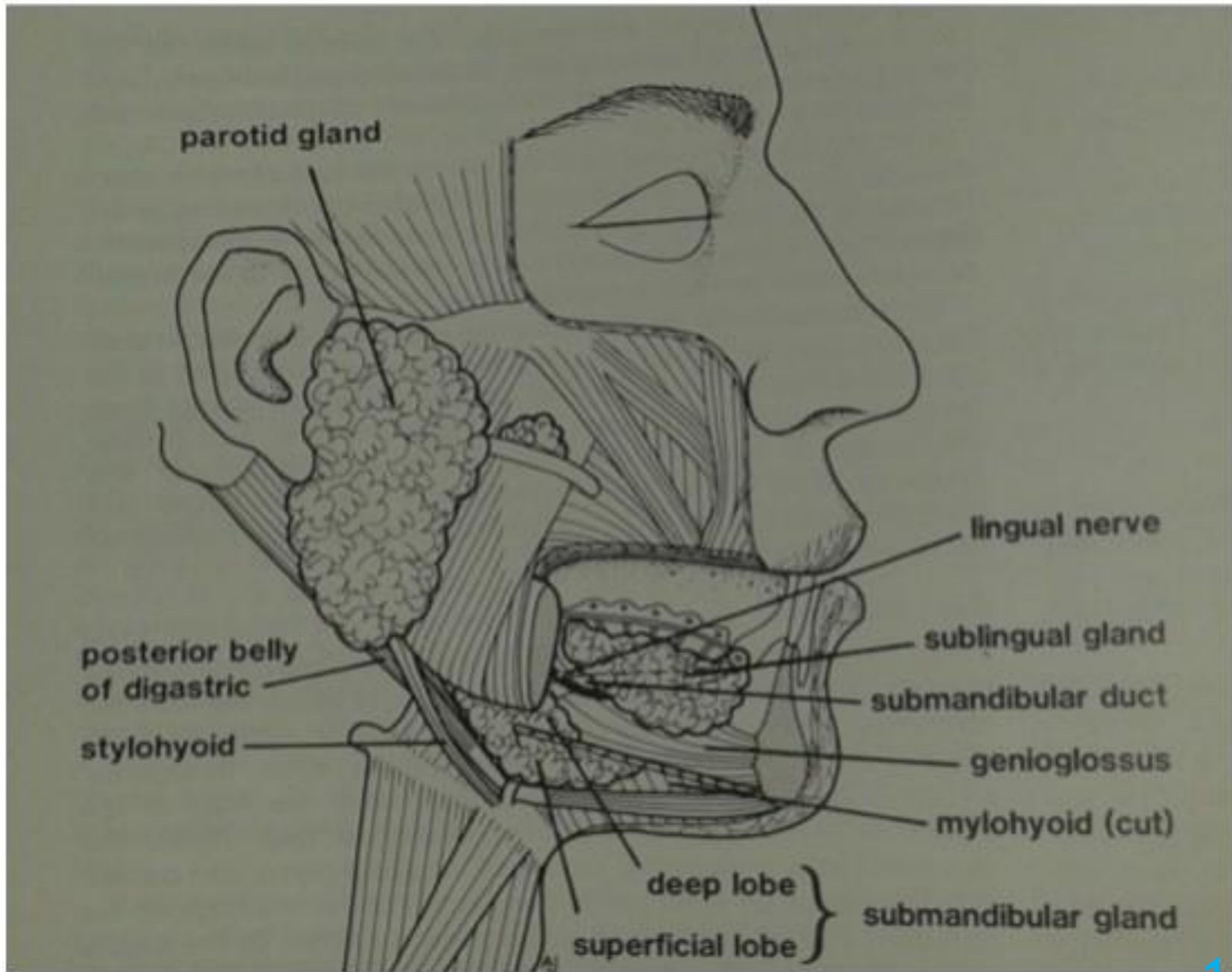
Salivary glands in the floor of the mouth

1. Submandibular gland: lies partially in the floor of the mouth and partially in the neck, consists of a superficial lobe situated in the neck lateral to the mylohyoid muscle, and a deep lobe lying in the floor of the mouth between mylohyoid and hyoglossus.

the superficial lobe is in contact with the medial surface of the mandible below the mylohyoid line (submandibular fossa).

The facial artery after curving over the posterior belly of digastric muscle runs down wards between the lateral surface of the superficial lobe and the medial surface of the mandible, usually in a deep curve in the gland.

At the lower border of the mandible the artery arches upwards into the face.



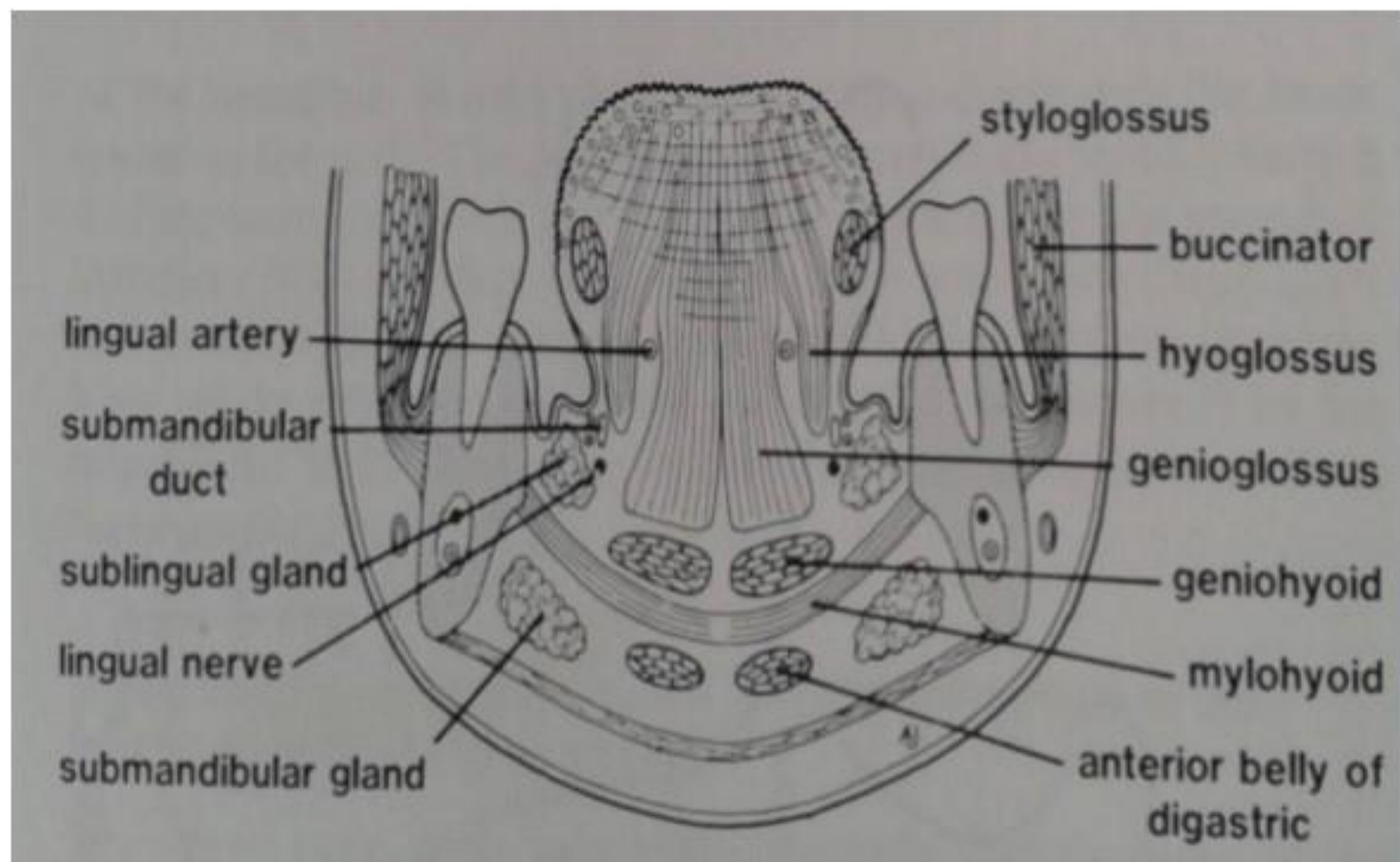


Fig. 4.89. Coronal section through the tongue and the floor of the mouth.

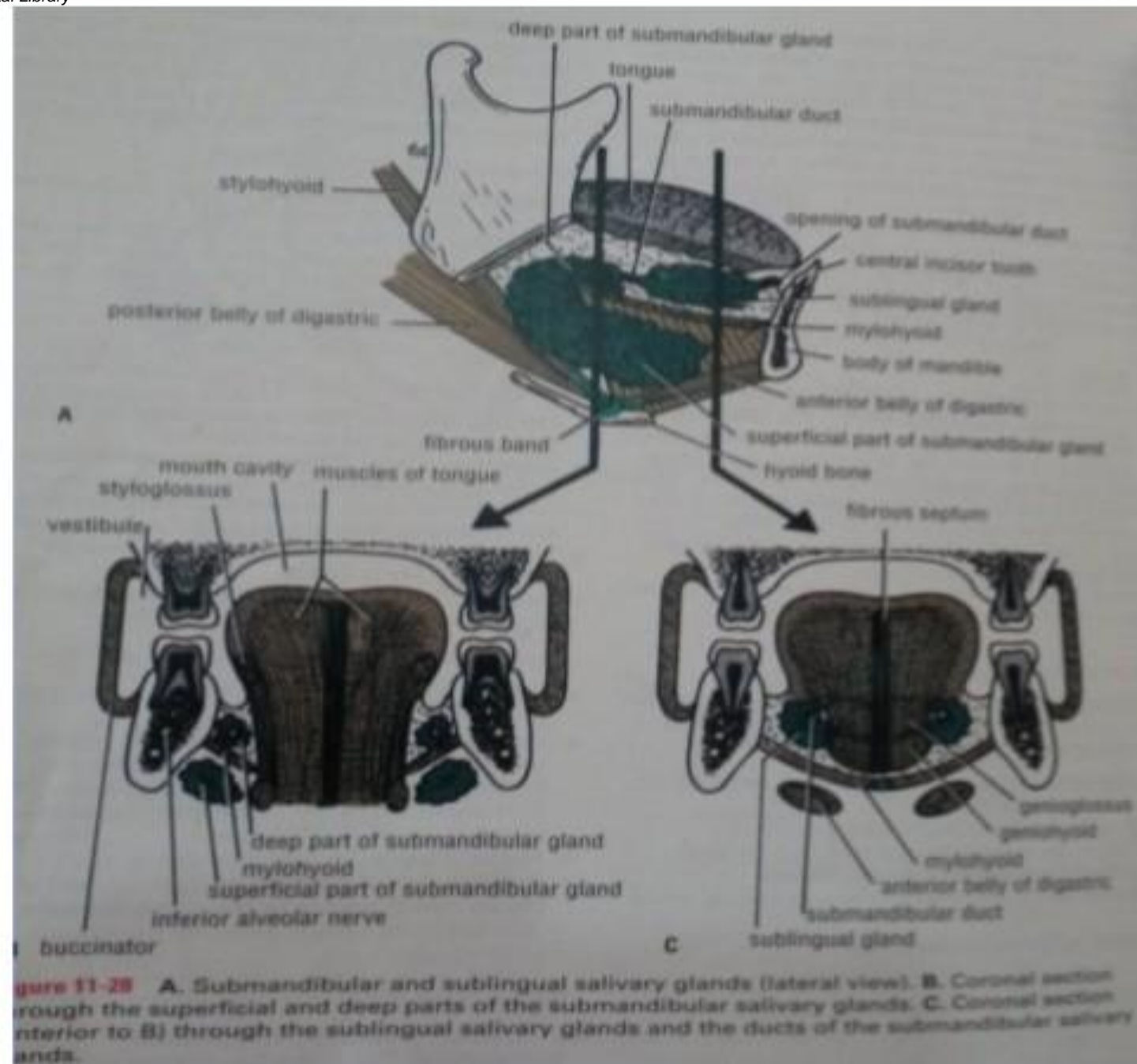


Figure 11-28 A. Submandibular and sublingual salivary glands (lateral view). B. Coronal section through the superficial and deep parts of the submandibular salivary glands. C. Coronal section anterior to B) through the sublingual salivary glands and the ducts of the submandibular salivary glands.

2. Sublingual gland: the smallest of the three main salivary gland . Situated in front of the deep lobe of the submandibular, between the mylohyoid laterally and the genioglossus medially extending from the opposite of the second molar to the premolar region.

- Its covered by the mucous membrane of the floor of the mouth which it raises to form the sublingual fold.
- Lateral surface of the gland comes in contact with the sublingual fossa on the medial surface of the body of the mandible
- The medial surface of the gland is crossed by the lingual nerve and submandibular duct. The gland opens onto the surface of the sublingual fold through a variable number (about 15) of small ducts called bartholins duct.
- Innervation: submandibular ganglion and para sympathetic fiber of chorda tympani.
- Blood supply and drainage: sublingual artery and vein.

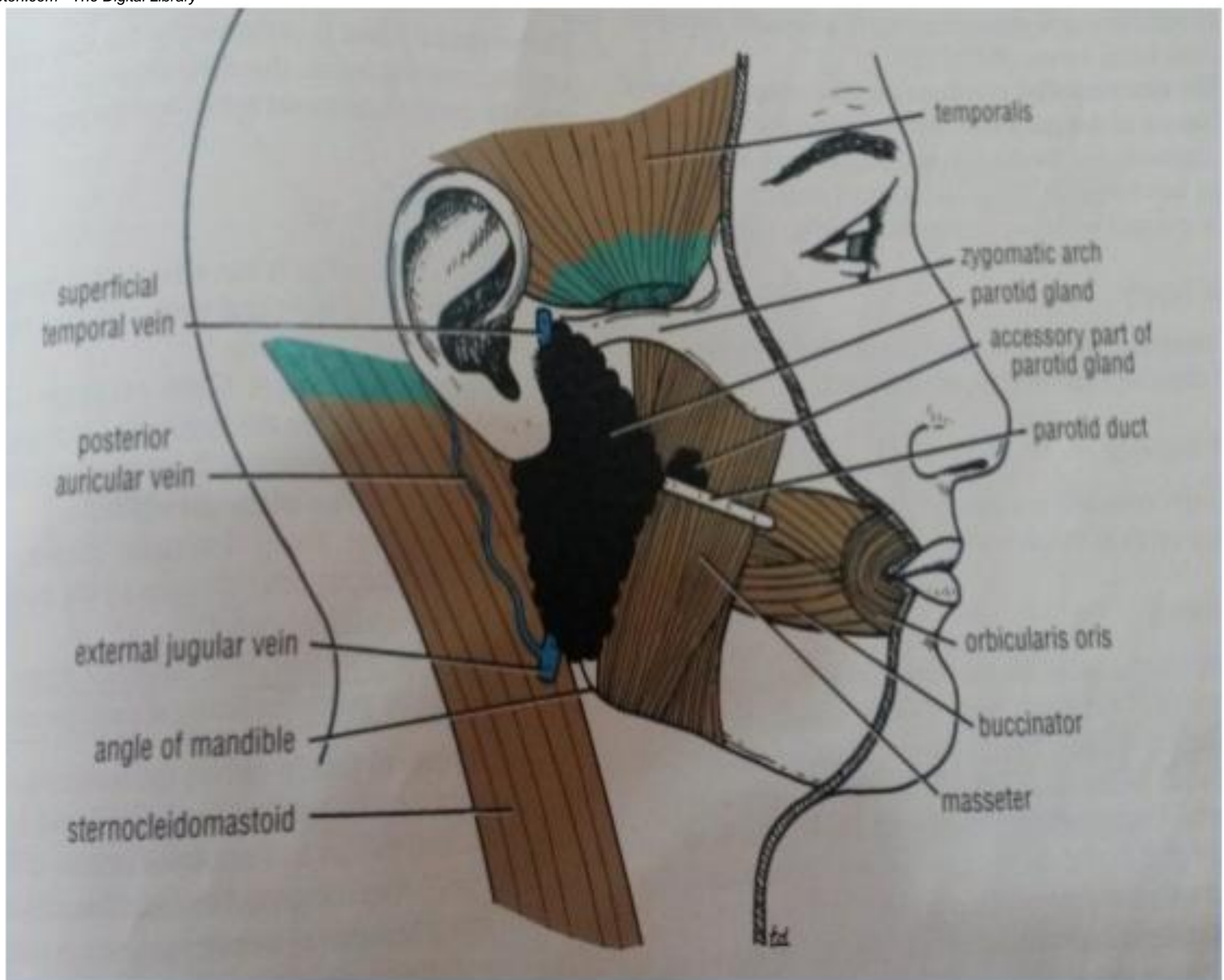
Clinical aspects:

- **Viral and bacterial infection and stone formation.**
- **Cysts may occur in the gland in the floor of the mouth sometimes as a result of chronic blockage of their ducts aswelling of this type referred to as a *Ranula*.**

Parotid gland

- The largest of the salivary gland .
- Mainly serous but contains a few scattered mucous acini.
- Occupies the region between the ramus in front and the mastoid process and sternocleidomastoid muscle behind.
- Pyramidal in shape. Its apex extends beyond the angle of the mandible and the base is closely related to the external acoustic meatus.
- surrounded by tough fibrous capsule(parotid capsule).
- The parotid duct(stensen's duct) appears at the anterior border of the gland and passes horizontally across the masseter muscle, it turns medially at the front edge of masseter, pierces the buccinator to terminate in the oral cavity opposite to the maxillary 2nd molar.

- The part overlying masseter maybe separated from the remainder of the gland and is then termed (accessory part of the gland).
- It has four surfaces, the small supeior surface is related to the cartiliginous part of the external acoustic meatus and the postirior aspect of the capsule of the temporomandibular joint. A small part of the gland projects medially between the joint and the meatus (glenoid lobe).
- The anteromedial surface abuts on the posterior borders of the mandibular ramus and the attach masseter and medial pterygoid muscles.
- The posteriomedial surface is related to the mastiod processes and the upper part of the anterior border of sternocleidomastiod.
- The superficial surface is flattened and is covered by subcutaneous tissue and skin.



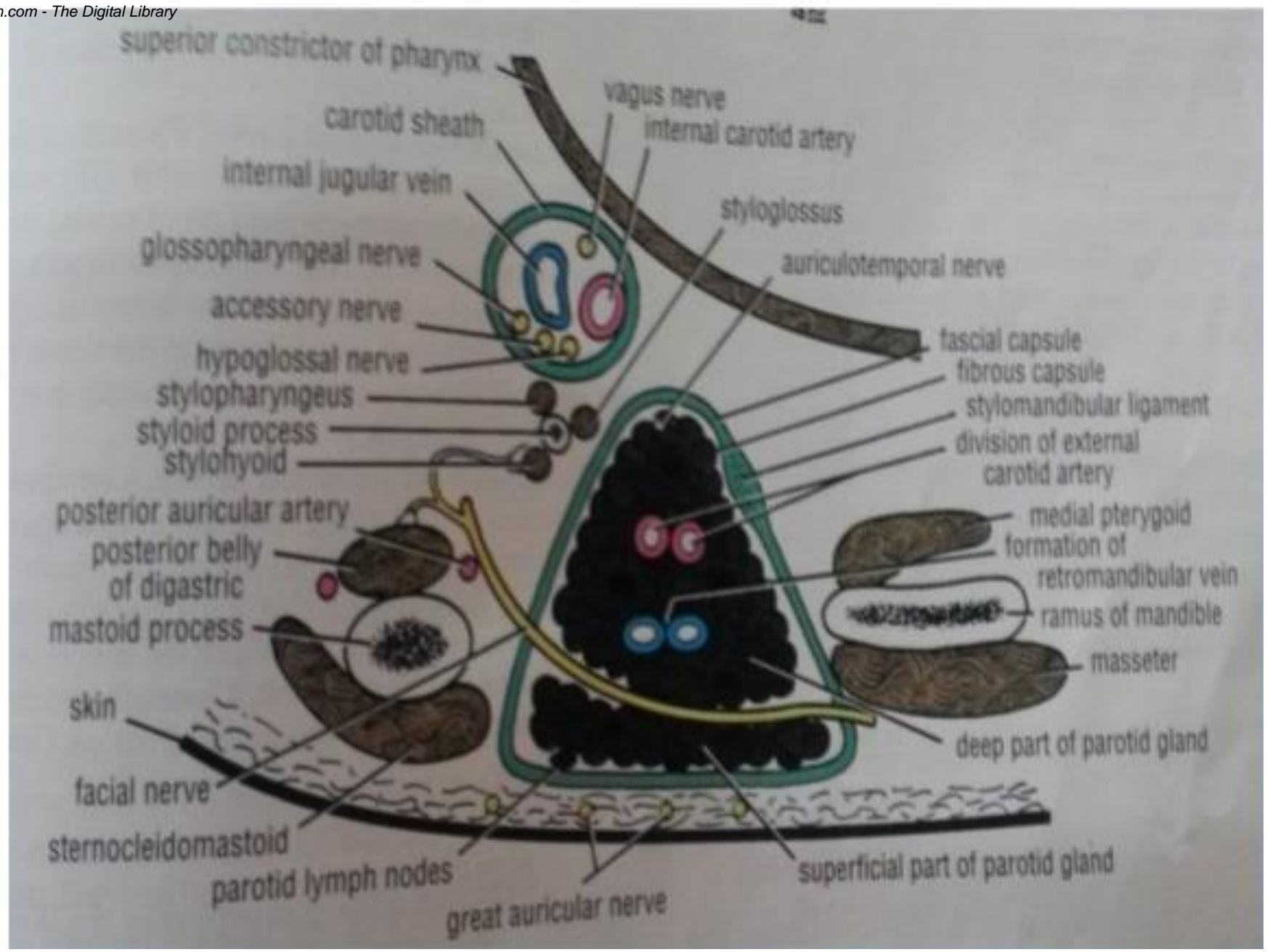
Structures within the gland:

1. *The external carotid artery:* Enter the gland through lower part of its posteriomedial surface divided into *maxillary artery* and *superficial temporal artery* .

2. *The retromandibular vein:* Formed by the union of maxillary and superficial temporal vein, it runs downwards lateral to the external carotid artery and in the lower part of the gland or after emerging therefrom splits into anterior and posterior divisions.

The posterior division joins the posterior auricular vein to form the external jugular vein. The anterior division joins the facial vein .

3. *The auriculotemporal nerve:* passes behind the temporomandibular joint runs through the glenoid lobe of the parotid gland or within its covering fascia.



4. *Facial nerve*: leaves the skull through the stylomastoid foramen. Enter the gland and divides into five or more branches which are interconnected to form the (parotid plexus).

A. *The temporal branches*: leave the upper part of the gland, crosses the zygomatic arch and supplies muscles of the external ear and part of frontalis.

B. *Zygomatic branch* (often double): supply the remainder of frontalis, the two parts of orbicularis oculi and adjacent muscle.

C. *The buccal branch* (often double): to the buccinator, the upper half of the orbicularis oris and the dilator muscles inserting into the upper lip.

D. *The mandibular branch*: emerges from lower border of the gland, passes into the neck across the lower border of the angle of the mandible, runs forward a short distance, and then crosses back into the face at the anterior border of the masseter muscle to supply the lower lip.

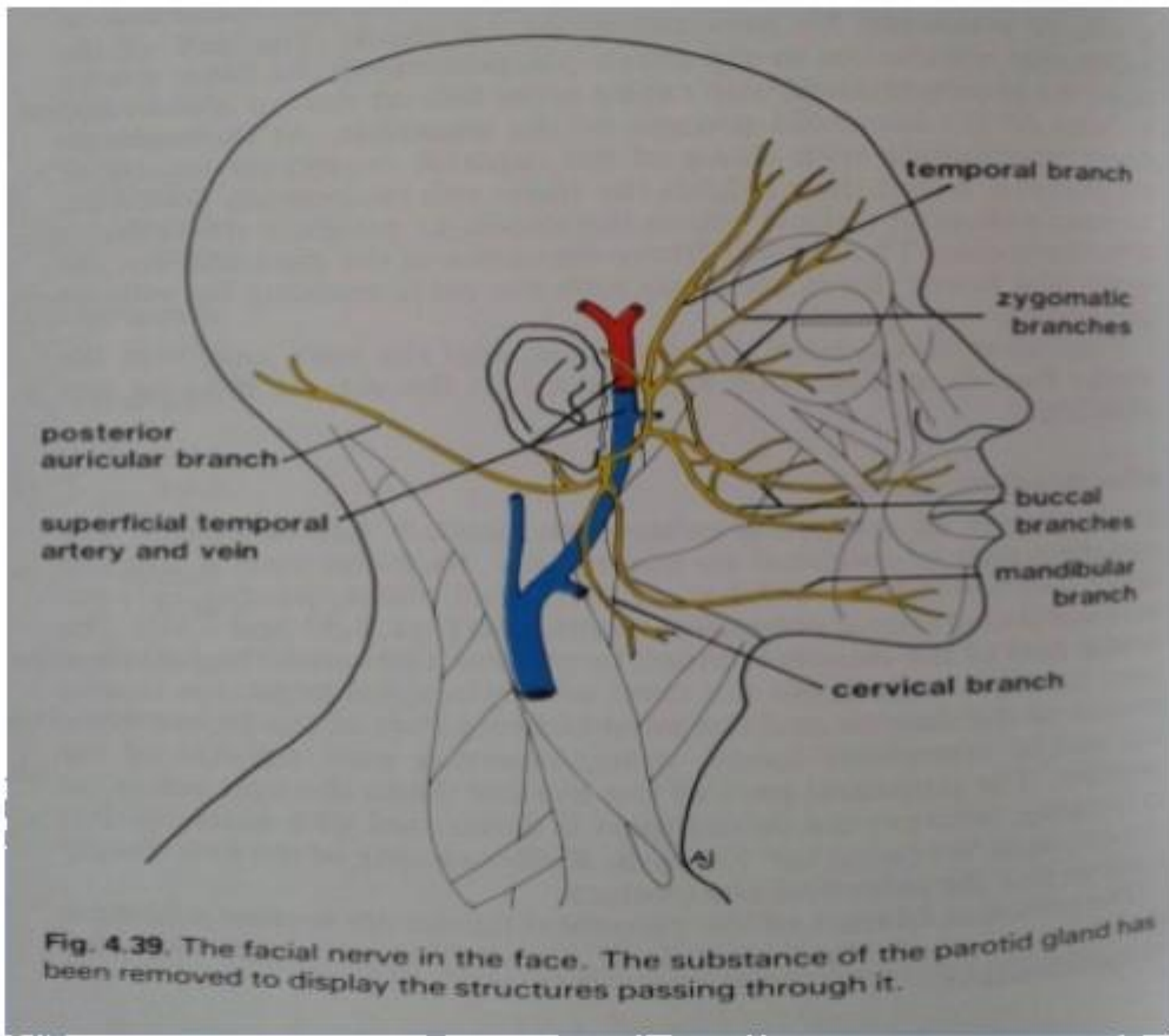
E. The cervical branches: runs vertically downwards behind the angle of the mandible to supply platysma.

Innervation:

Sympathetic supply from the superior cervical ganglion of the sympathetic trunk result in a reduced secretion of saliva which is low in organic content.

Parasympathetic innervation the pre ganglionic fibers begin in the inferior salivatory nucleus in the medulla, leave the brainstem in the glossopharyngeal nerve and pass through its tympanic branch, the tympanic plexus, and the lesser petrosal nerve to the otic ganglion where they synapse with postganglionic fibers which pass to the gland in the auriculotemporal nerve.

Parasympathetic innervation leads to the production of copious saliva rich in mucus and enzymes.



Clinical aspect:

Inflammation the commonest cause of this is mumps, a viral infection occurs most frequently in children.

Acute and chronic parotitis may also result from infections ascending from the mouth through the parotid duct.

when inflamed the gland is swollen and painful and, in chronic cases the flow of saliva is reduced.

A swollen gland maybe due to a stone lodged in the duct.

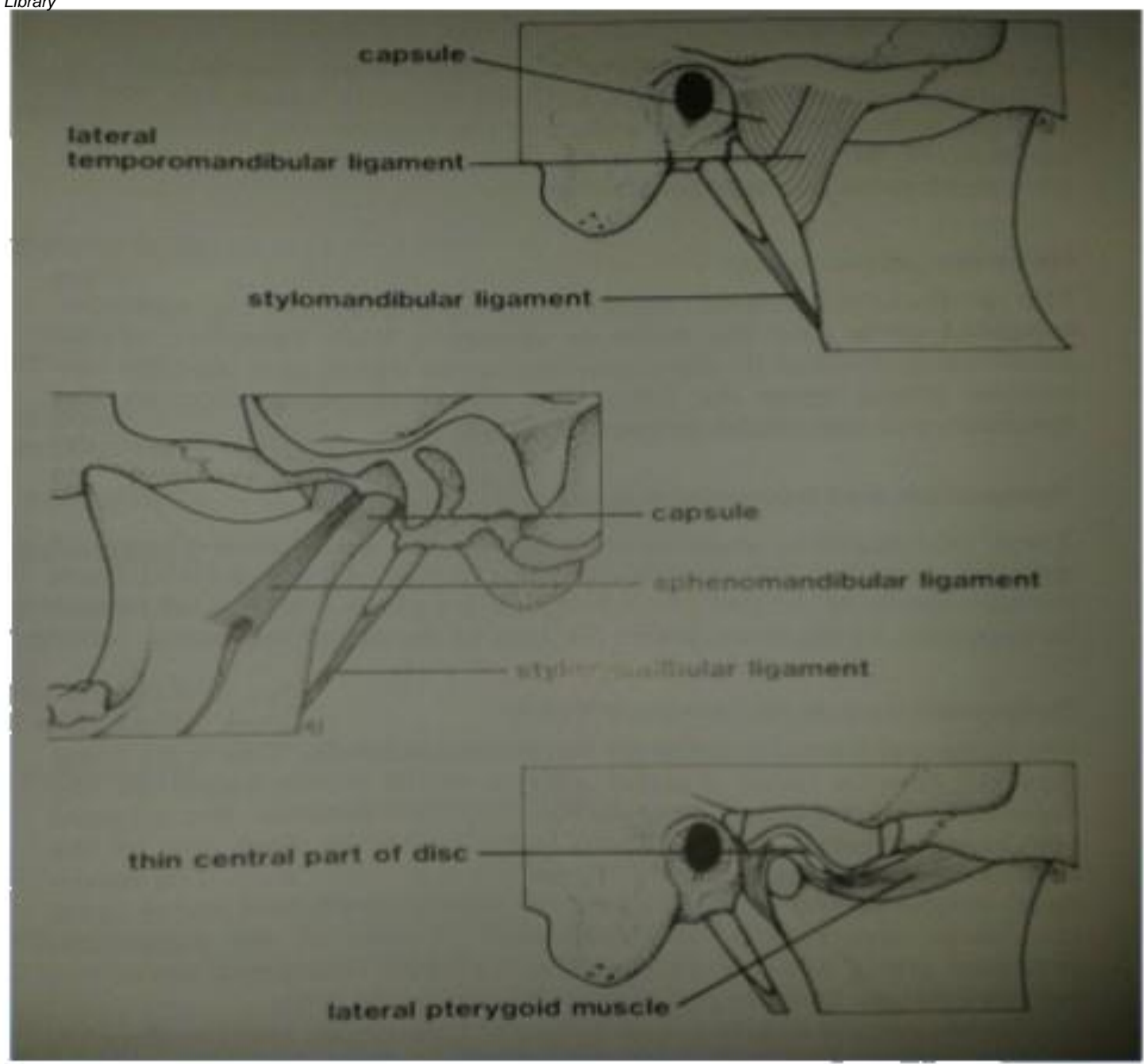
Benign(pleomorphic adenoma) and malignant tumors mixed parotid tumor which is locally invasive but doesn't usually metastasize.

In operating to remove a tumor care must be taken to avoid damaging the facial nerve.

Tempromandibular joint

The tempromandibular joints are the only freely movable articulation in the skull.

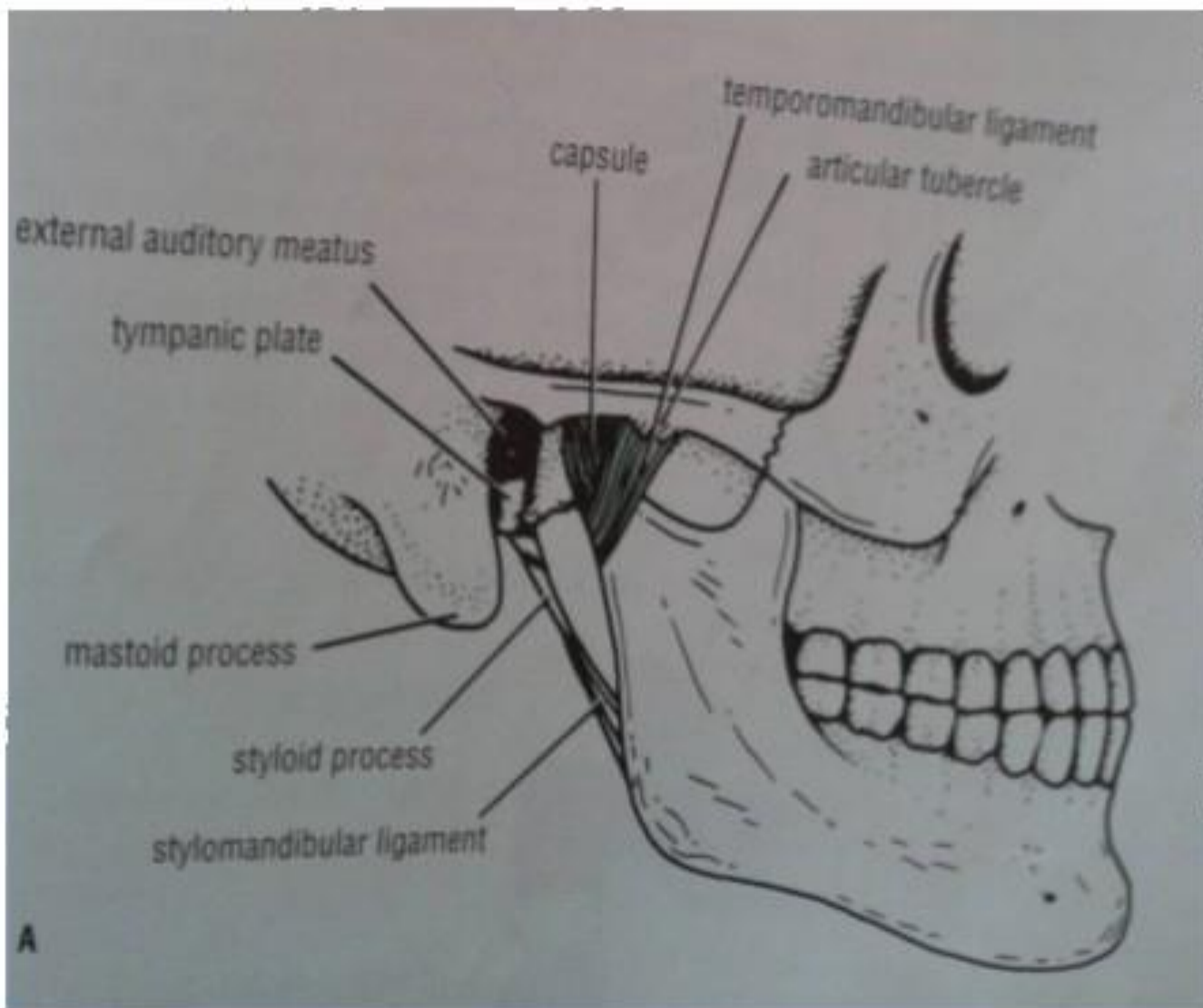
- The joint space is divided into two cavities (upper and lower) by intra-articular disc. The upper joint space allows for gliding movements. The lower joint space for hinge movements.
- The articular surfaces are not composed of hyaline cartilage but of fibrous tissue. This reflects the joints' intramembranous development.
- A secondary condylar cartilage is present in the head of the condyle until adolescence.
- Movement of the joint is influenced by the teeth.
- There are two TMJs associated with a single mandible: this has considerable functional significance as movement at one joint is accompanied by movement at the other.



Mandibular fossa: is an oval depression in the temporal bone lying immediately anterior to the external acoustic meatus. The shape of the mandibular fossa does not exactly confirm to the shape of the mandibular condyle, the intra-articular disc moulding together the joint surface. The bone of the central part of the fossa is thin.

Mandibular condyle: from above the condyle is roughly ovoid in outline, the anterior posterior dimension being about half the mediolateral dimension. The medial aspect is wider than the lateral.

- ***Joint capsule:*** Thin, slack, cuff that doesn't limit mandibular movement and is too weak to provide much support for the joint. Above, it's attached to the mandibular fossa, extending anteriorly to just in front of the crest of the articular eminence, posteriorly to the squamo-tympanic and petrotympanic fissures, medially to the medial glenoid plane and laterally between the lateral margin of the articular eminence and the postglenoid process. Below, it's attached to the neck of the condyle. Internally, it's attached to the intraarticular disc and is lined by synovial membrane. The capsule is richly innervated.



Synovial membrane: lines the inner surface of the fibrous capsule and the margins of the intra-articular disc but does not cover the articular surface of the joint.

The synovial membrane secretes the synovial fluid that occupies the joint cavities, lubricates the joint and presumably also has nutritive functions.

At rest, the hydrostatic pressure of the synovial fluid has been reported as being subatmospheric, but this is greatly elevated during mastication.

Temporomandibular ligament: The joint capsule is strengthened by the temporomandibular ligament laterally. The temporomandibular ligament inserts onto the posterior surface of the condyle. This ligament provides the main means of support for the joint restricting backward and inferior movements of the mandible and resisting dislocation during functional movements.

The temporomandibular ligament is reinforced by a horizontal band of fibers running from the articular tubercle to the lateral surface of the condyle which restricts the posterior movement.

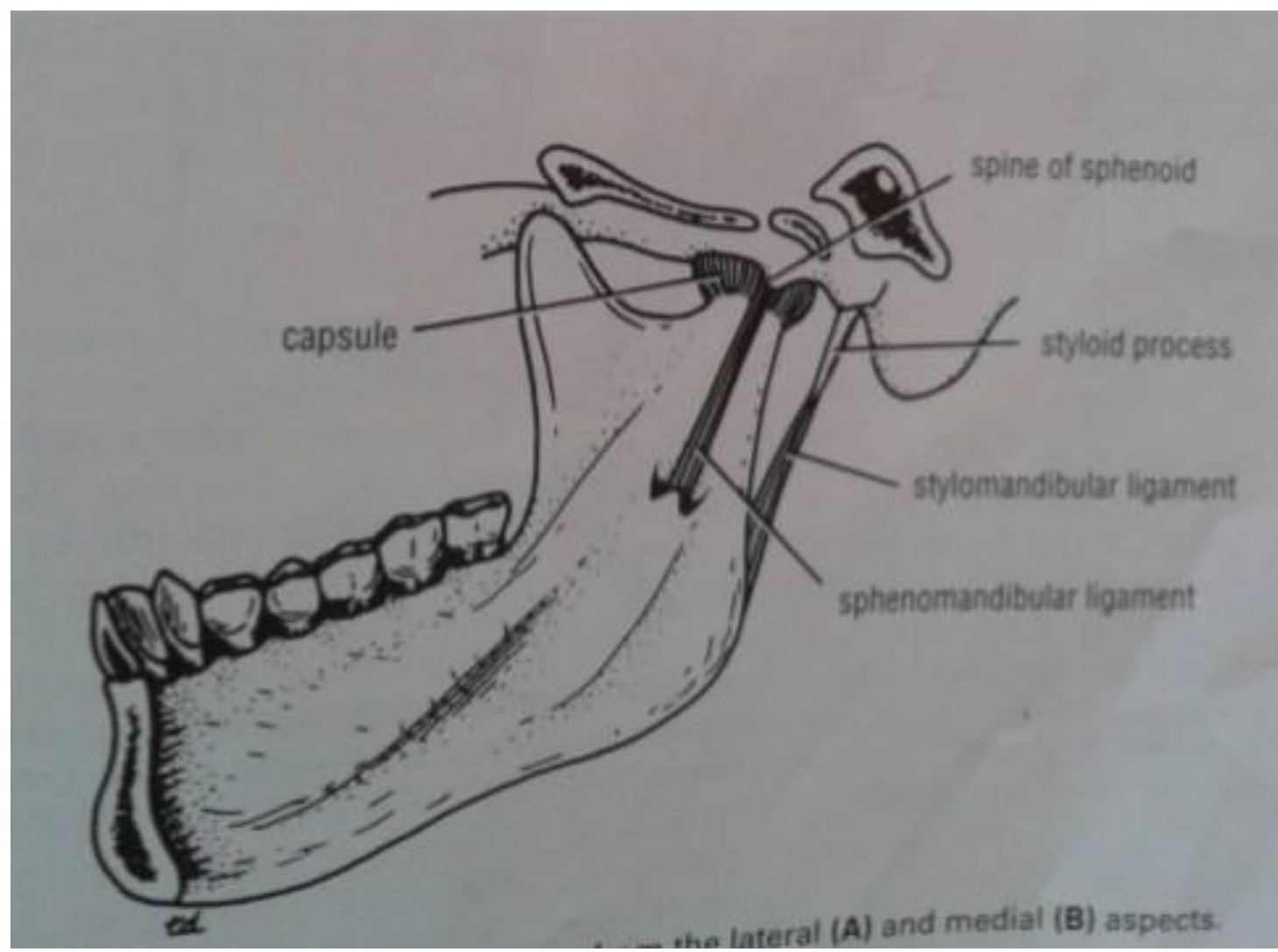
Medial displacement is prevented by the temporomandibular ligament of the opposite side.

Accessory ligaments:

- **The sphenomandibular ligament.**
- **The stylomandibular ligaments.**
- **The pterygomandibular raphe.**
- **The retinacular ligament.**

Intra-articular disc:

- **The articular disc is a plate of fibrocartilage which in the majority of cases completely divides the joint cavity into an upper and lower compartment. Occasionally the disc is perforated and the two compartment are then in communication.**



Laterally and medially the disc blends with the capsule of the joint. In front its attached to the anterior border of the squameous articular surface as well as to the capsule.

Posteriorly the disc is divided into two layers. The upper layer is attached to the anterior margin of the squamotympanic fissure while the lower layer is attached to the posterior surface of the neck of the mandible.

The lateral pterygoid muscle is inserted into the anterior margin of the disc through its attachment to the capsule.

The upper surface of the disc is slightly concave anteriorly and markedaly convex posetiorurly. The under surface is concave over its whole extent.

The disc is not of uniform thickness. The central part is thinnest and is relatively avascular. The posterior part of the disc consists of a thick layer of loose vascular tissue and contains many blood vessels and sensory nerve endings.

The TMJ is richly innervated (auriculotemporal, masseteric and deep temporal nerves of the mandibular division of the trigeminal nerve).

Blood supply: superficial temporal and maxillary arteries.

PROPHET (PEACE BE UPON HIM) SAID:

THE TWO UNITS OF THE SUNNAH OF

FAJR

ARE BETTER THAN

THE WORLD



&

ALL IT CONTAINS



Thank you for reading

Find more e-books and articles on Ketabton - your multilingual digital library.

www.ketabton.com

Ketabton - Pashto, Farsi, Arabic & English